Balgrist
Universitätsklinik

# TIPPS bei Handproblemen in der Hausarztpraxis




**PD Dr. med. Reissner Lisa**

Leitende Ärztin Handchirurgie

Universitätsklinik Balgrist

Lisa.reissner@balgrist.ch


Universität Zürich[UZH]

swiss olympic Medical Center

# LANDMARKEN



# TENDOVAGINITIS DE QUERVAIN
## FINKELSTEIN/EICHHOFF TEST

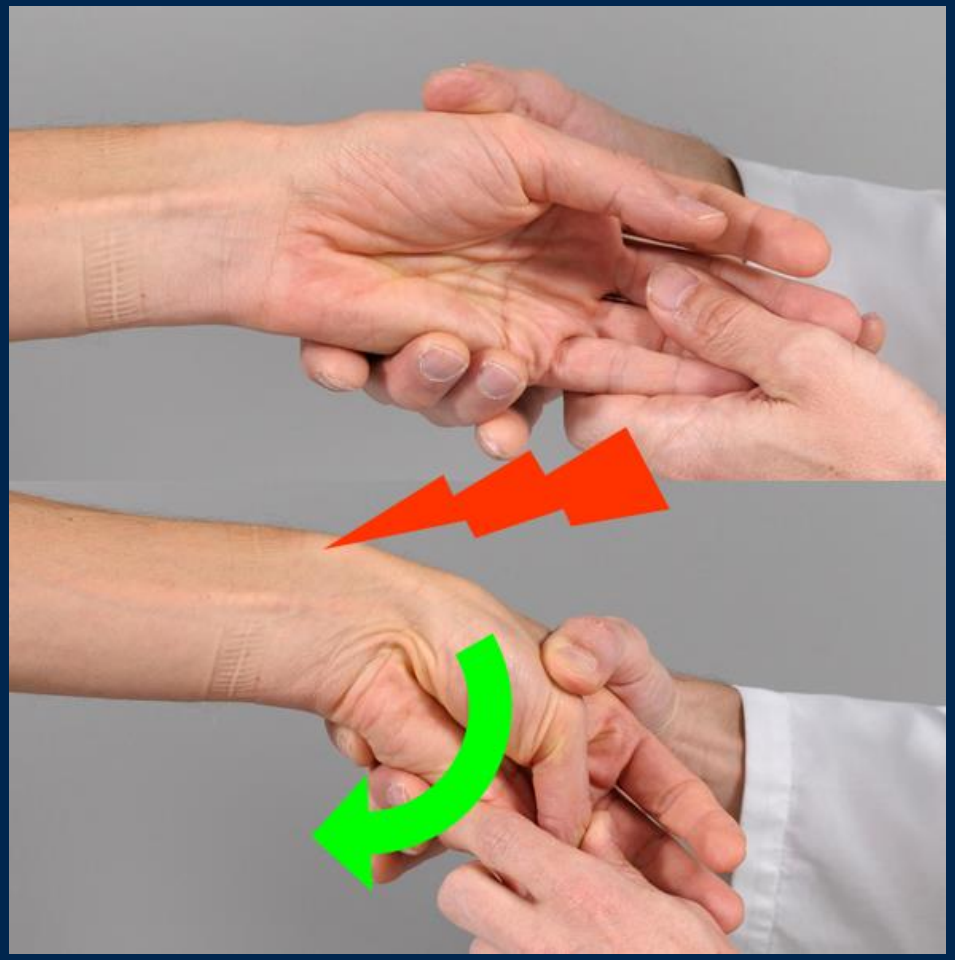



Finkelstein H. J Bone Joint Surg 1930;509–540 4

Eichhoff E. Bruns Beit Klin Chir. 1927:746–755

# TENDOVAGINITIS DE QUERVAIN
## SONOGRAPHIE

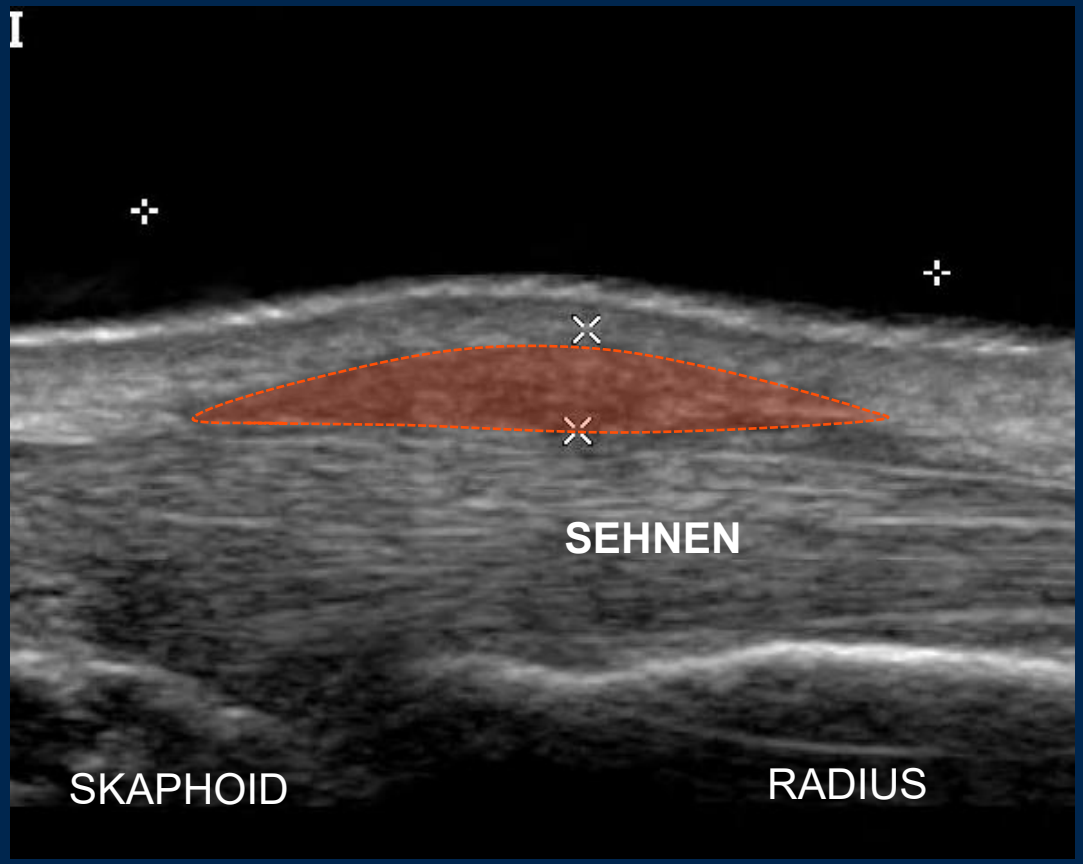


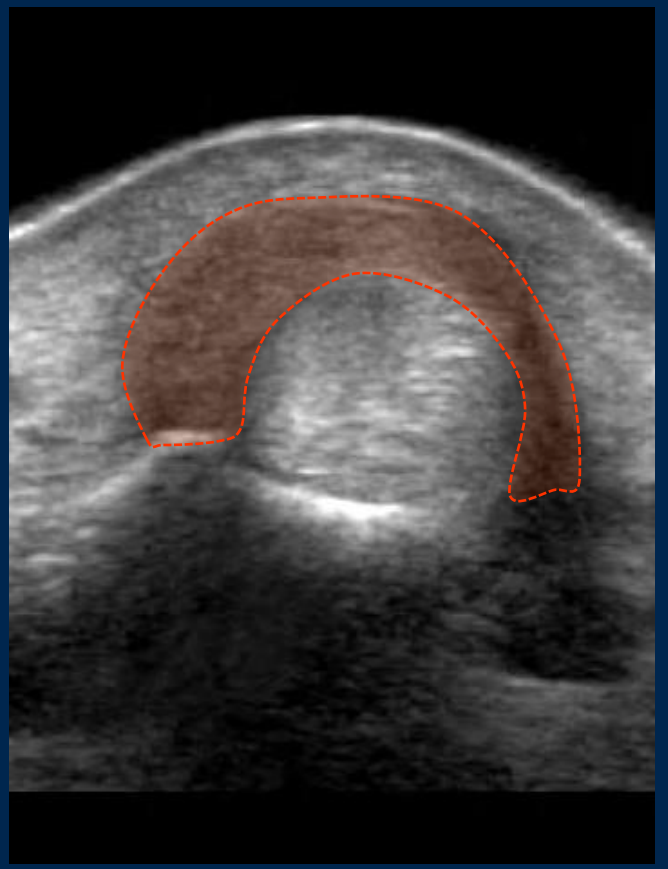

# TENDOVAGINITIS DE QUERVAIN
## HANDGELENKSMANSCHETTE MIT DAUMENEINSCHLUSS



# TENDOVAGINITIS DE QUERVAIN
## INFILTRATION MIT STEROID

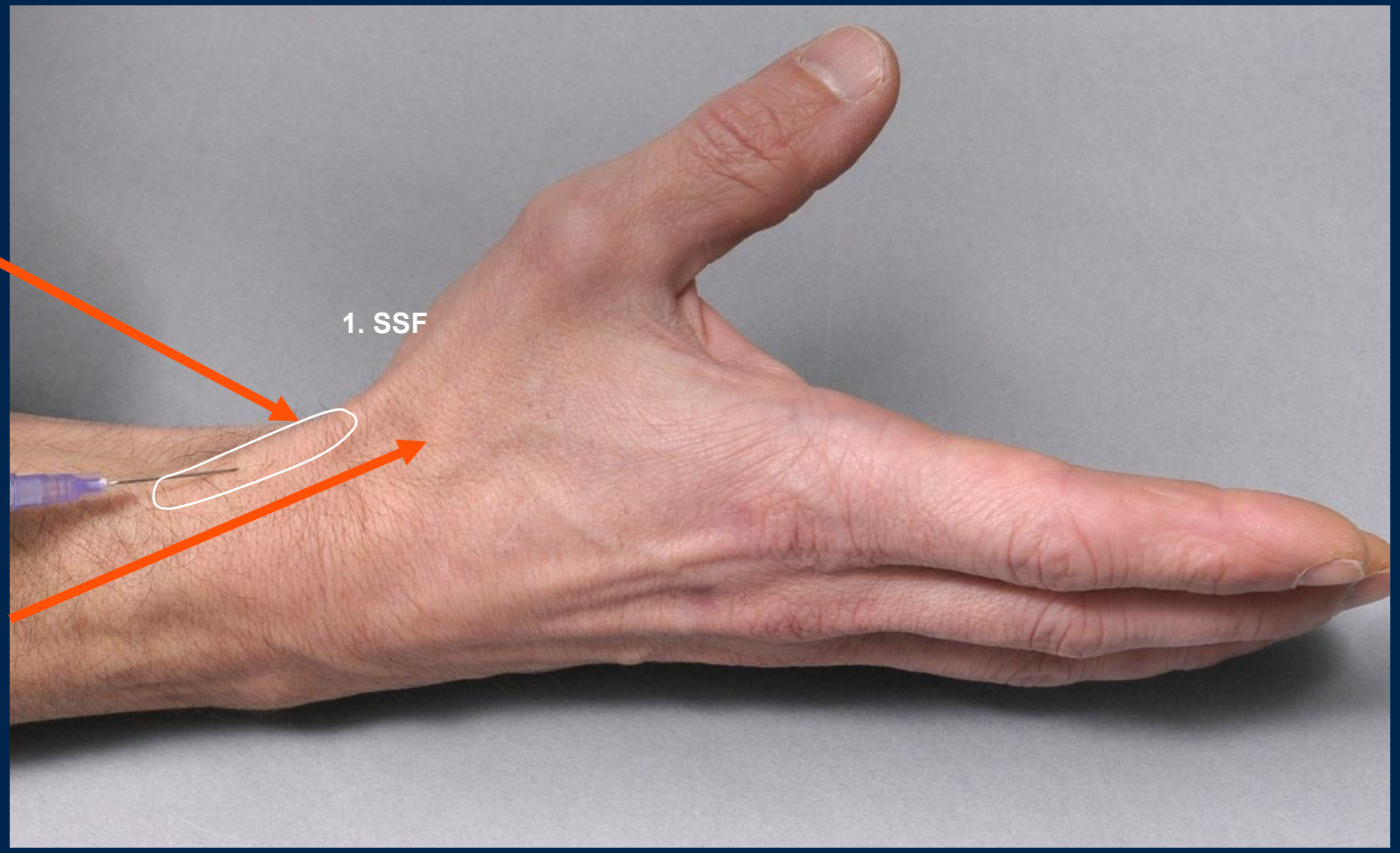

# TENDOVAGINITIS DE QUERVAIN
## ULTRASCHALLGESTEUERTE INFILTRATION

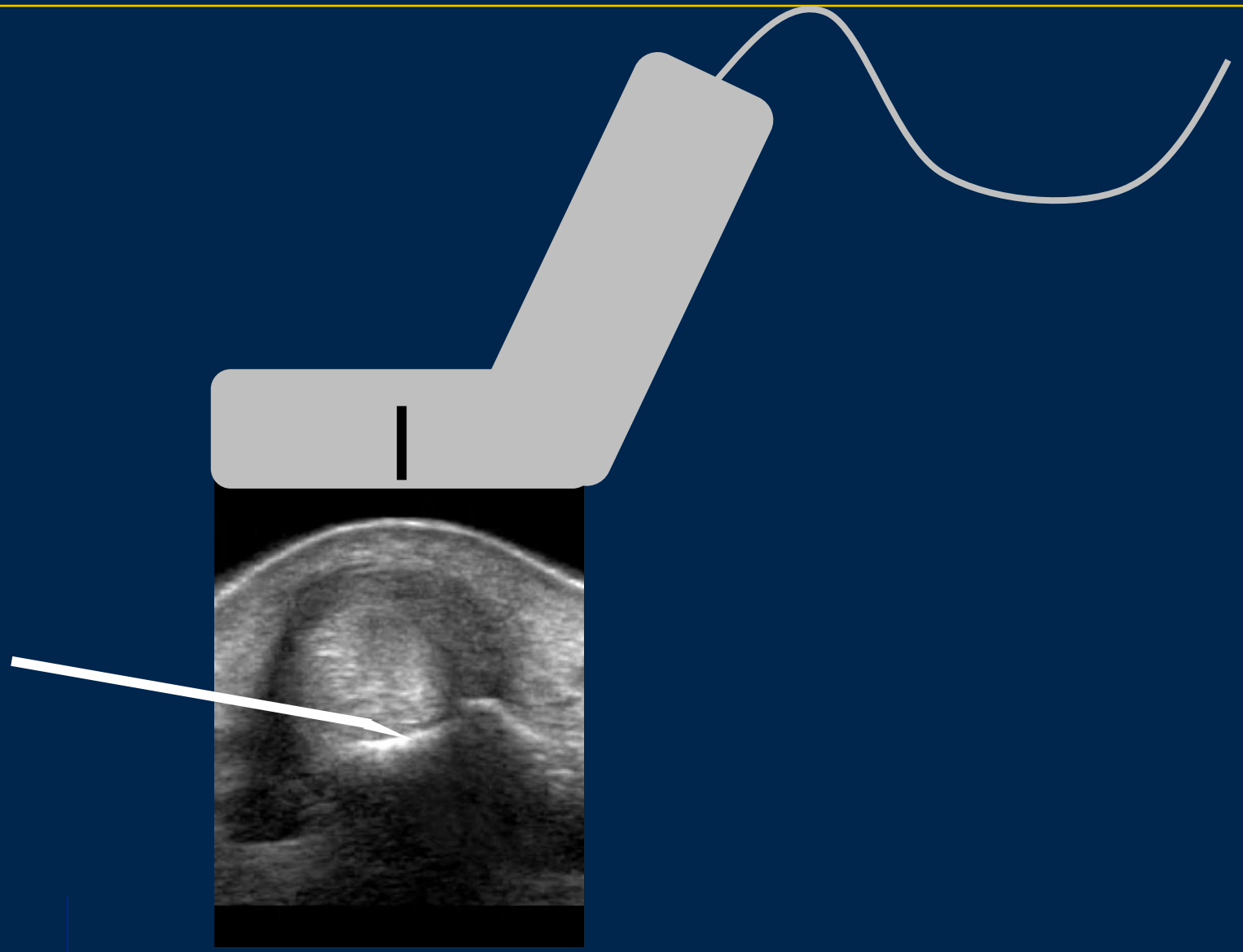

# TENDOVAGINITIS DE QUERVAIN
## OPERATION



# UNTERSUCHUNG
## EXTENSOR POLLICIS LONGUS



# HANDGELENK TRAUMA / DISTORSION

- > 2 -3 Wochen Schmerz ohne Besserung = Abklärung
- Ausschluss Skaphoidfraktur mittels Computertomographie



# SKAPHOIDPSEUDARTHROSE

## Scaphoid Nonunion Advanced Collapse



# SNAC
## THERAPIEOPTIONEN






# RHIZARTHROSE








# RHIZARTHROSE
## MAHLTEST

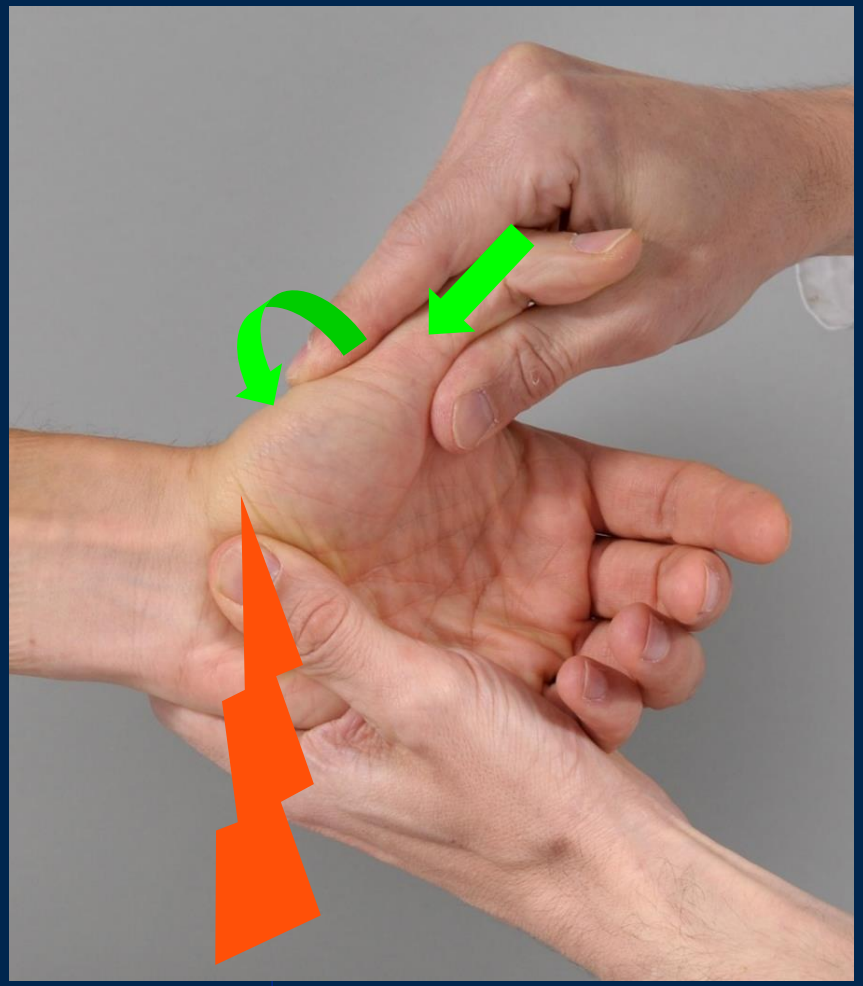

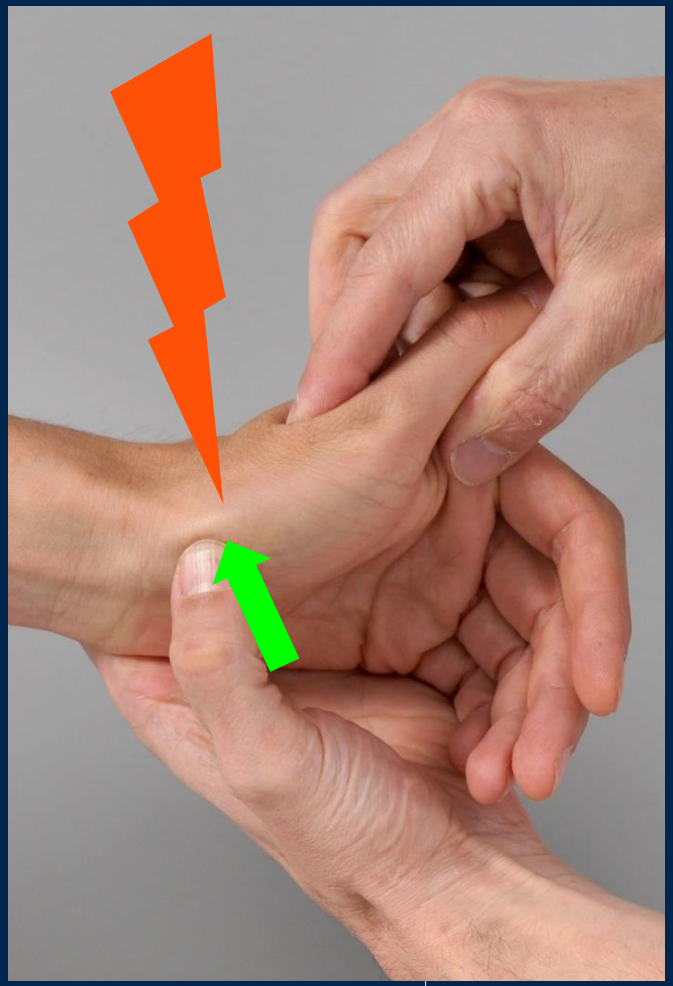

# RHIZARTHROSE
## MAHLTEST



# RHIZARTHROSE
## DAUMENNEOPRENMANSCHETTE



# RHIZARTHROSE
## INFILTRATION MIT STEROID

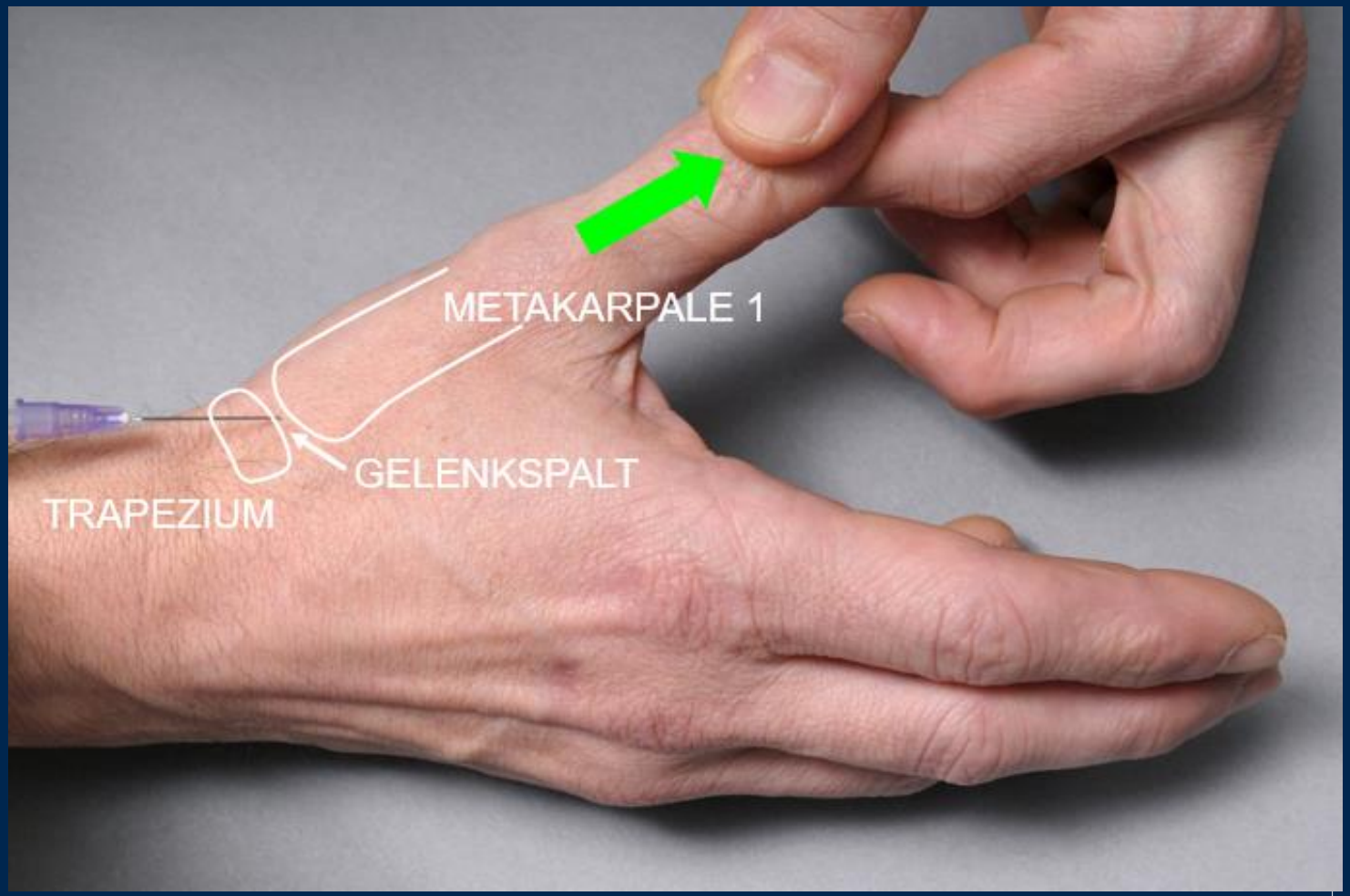

# RESEKTION-SUSPENSION-INTERPOSITIONS-ARTHROPLASTIK

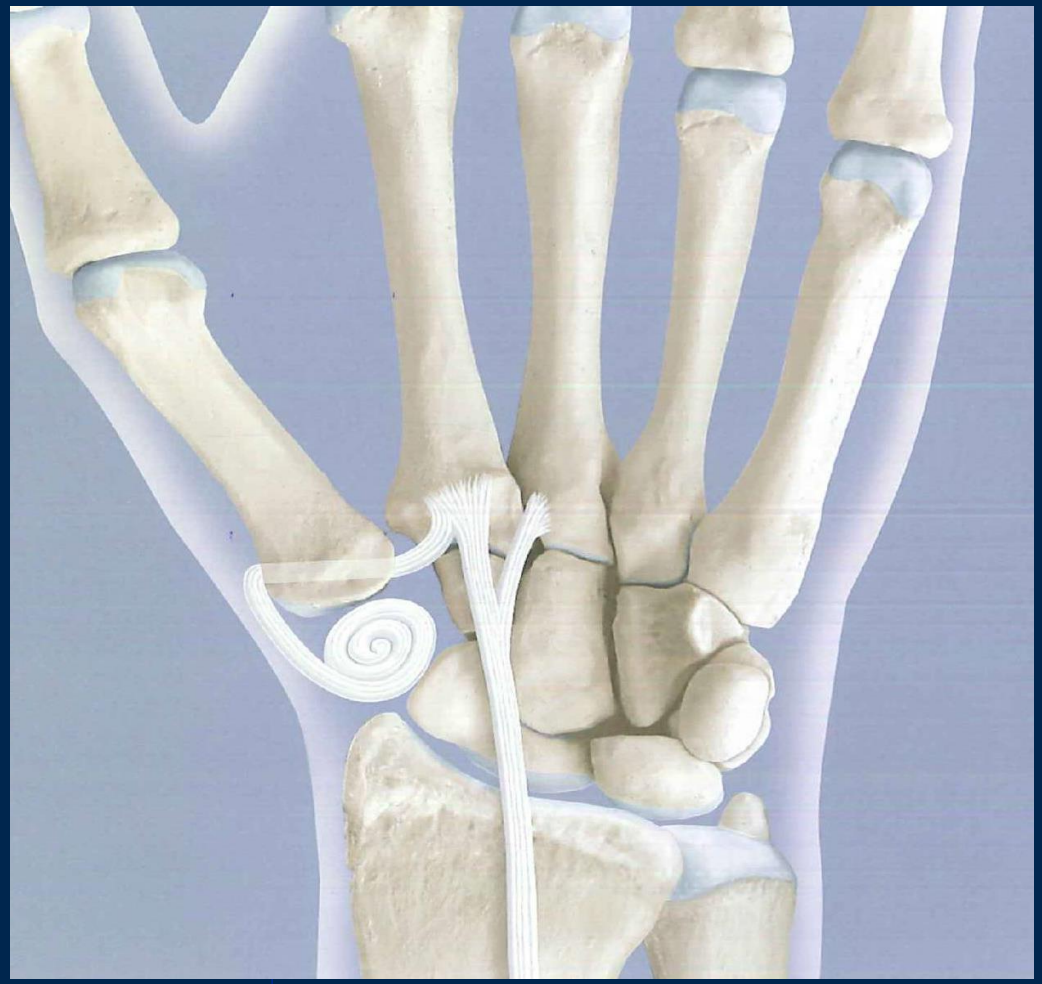



# RESEKTION-SUSPENSION-INTERPOSITIONS-ARTHROPLASTIK

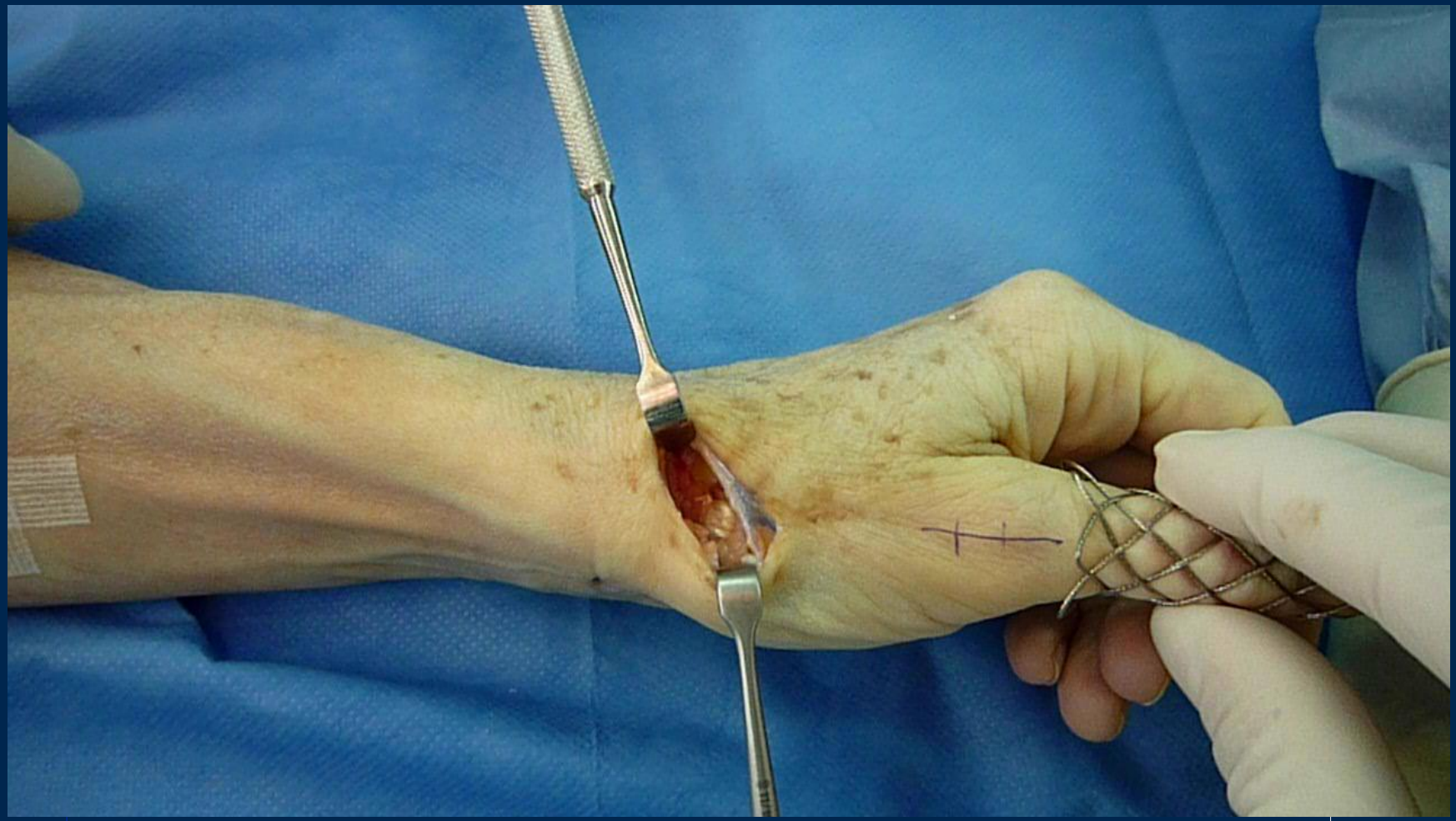

# RHIZARTHROSE
## ARTHRODESE



# RHIZARTHROSE
## IMPLANTATION PYROCARDAN





# RHIZARTHROSE
## TOUCHPROTHESE






# RHIZARTHROSE
## UMSTELLUNGSOSTEOTOMIE MC I

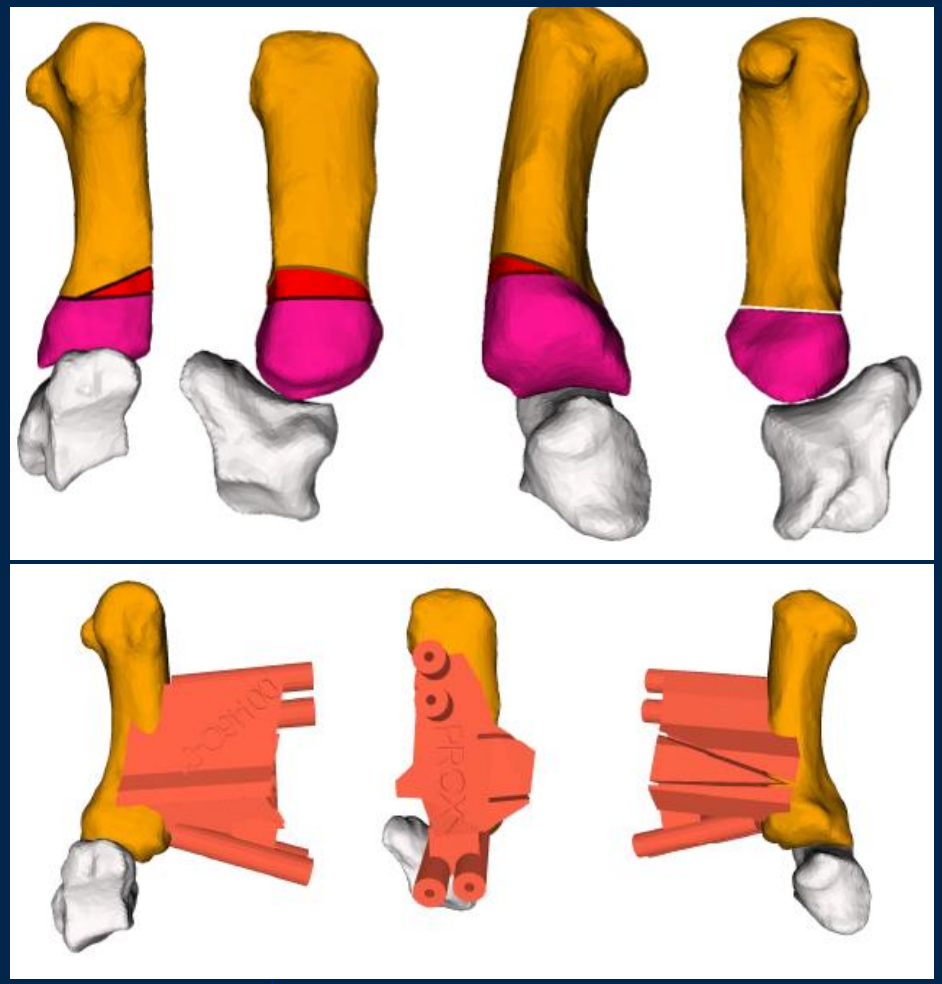







Wilson. Br J Surg, 1983

# RUPTUR ULNARES SEITENBAND MP I
## (SKIDAUMEN)

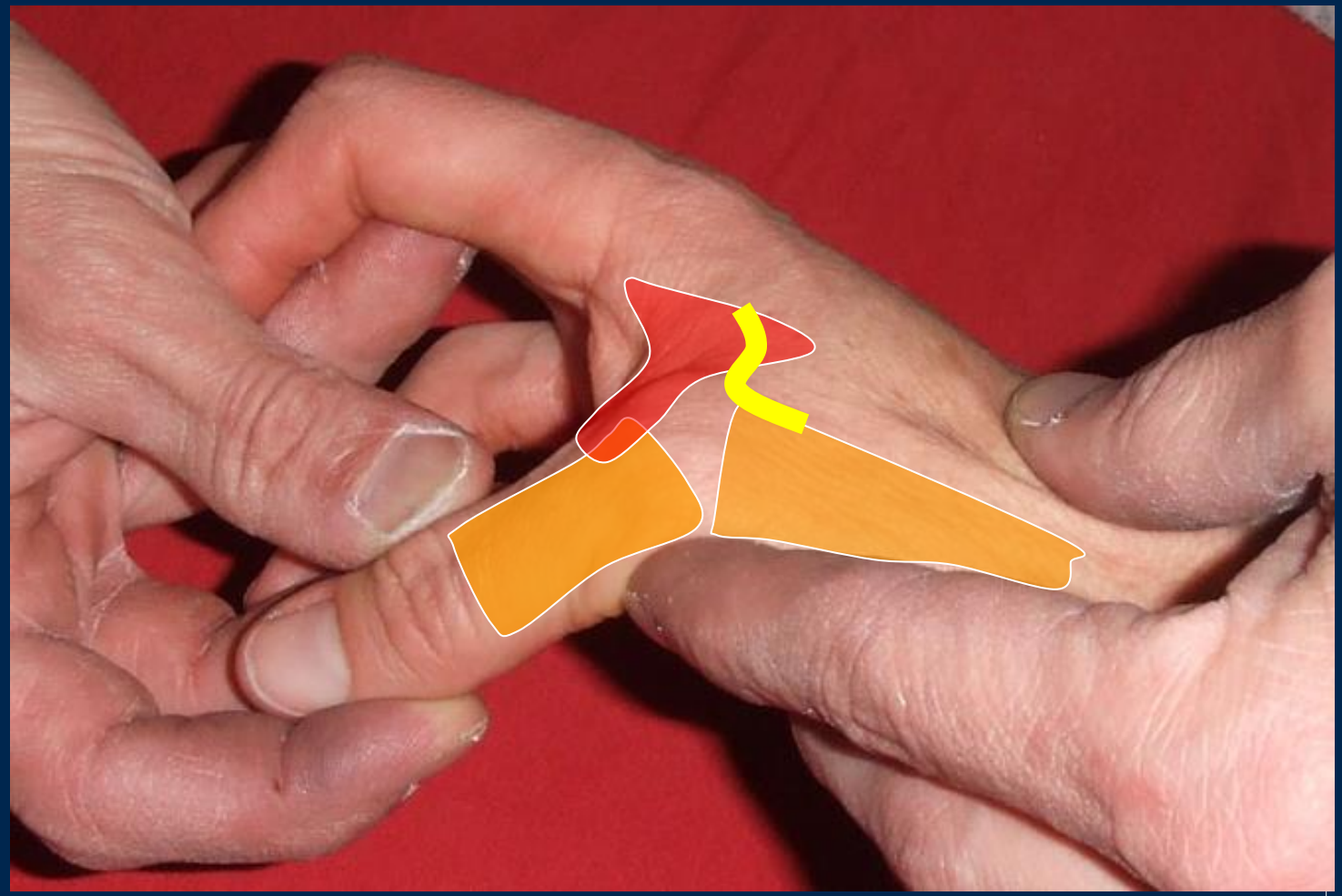

# RUPTUR ULNARES SEITENBAND MP I
## (SKIDAUMEN)



# RUPTUR ULNARES SEITENBAND MP I
## (SKIDAUMEN)



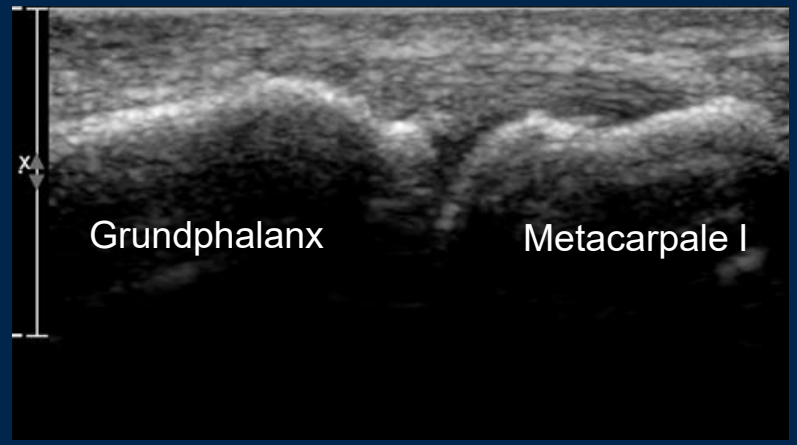


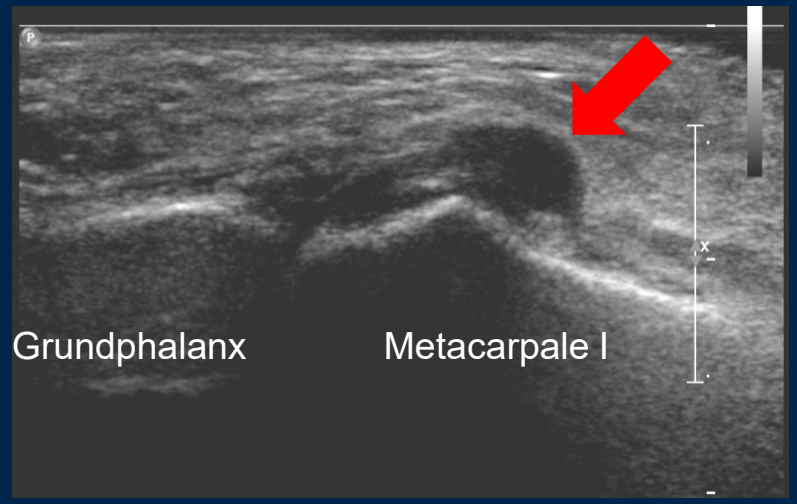

# „SKIDAUMEN“: CAVE STENER LÄSION

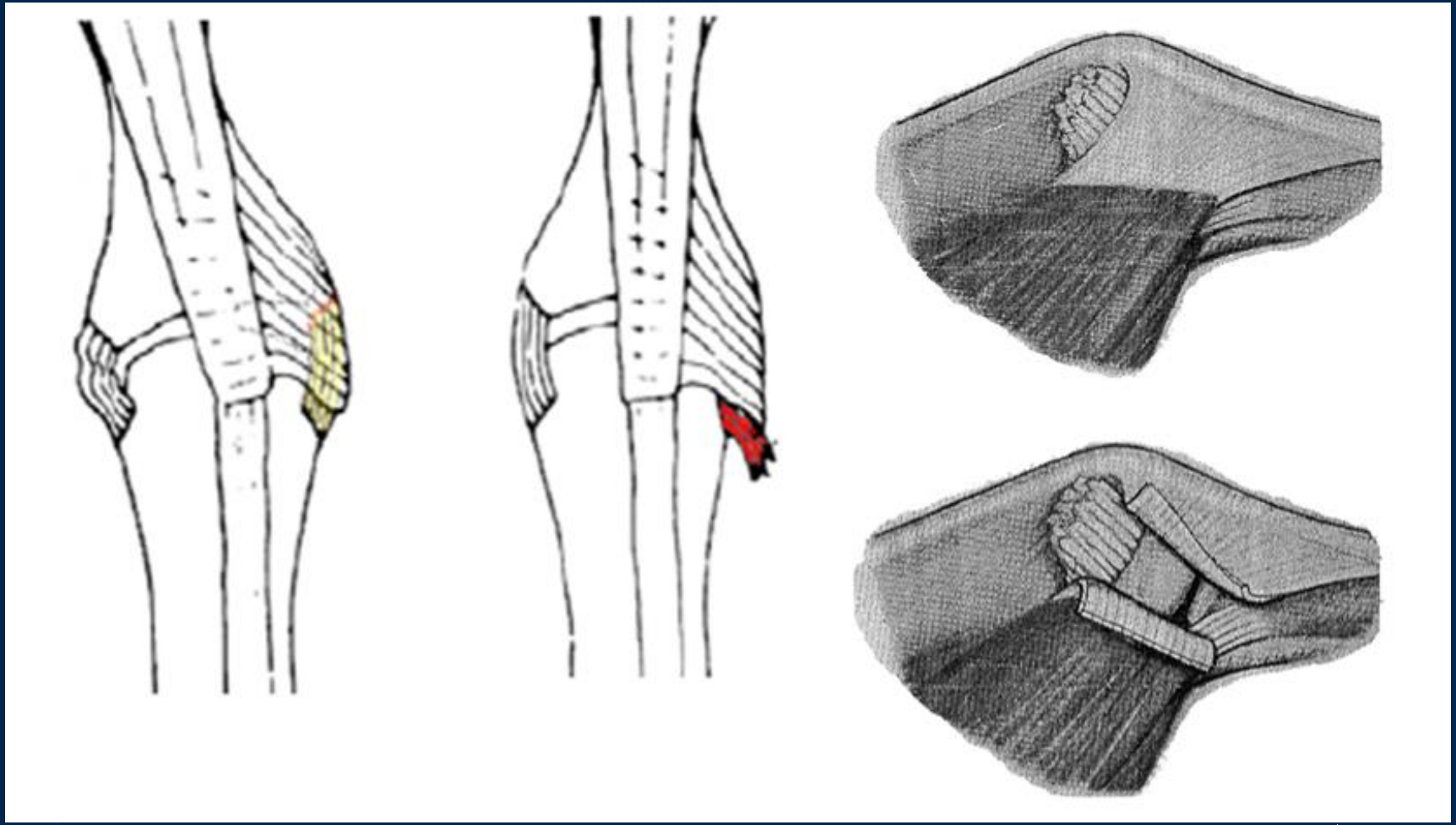

Stener B. Acta Chir Scand 1963;125:583-6

# STENER-LÄSION

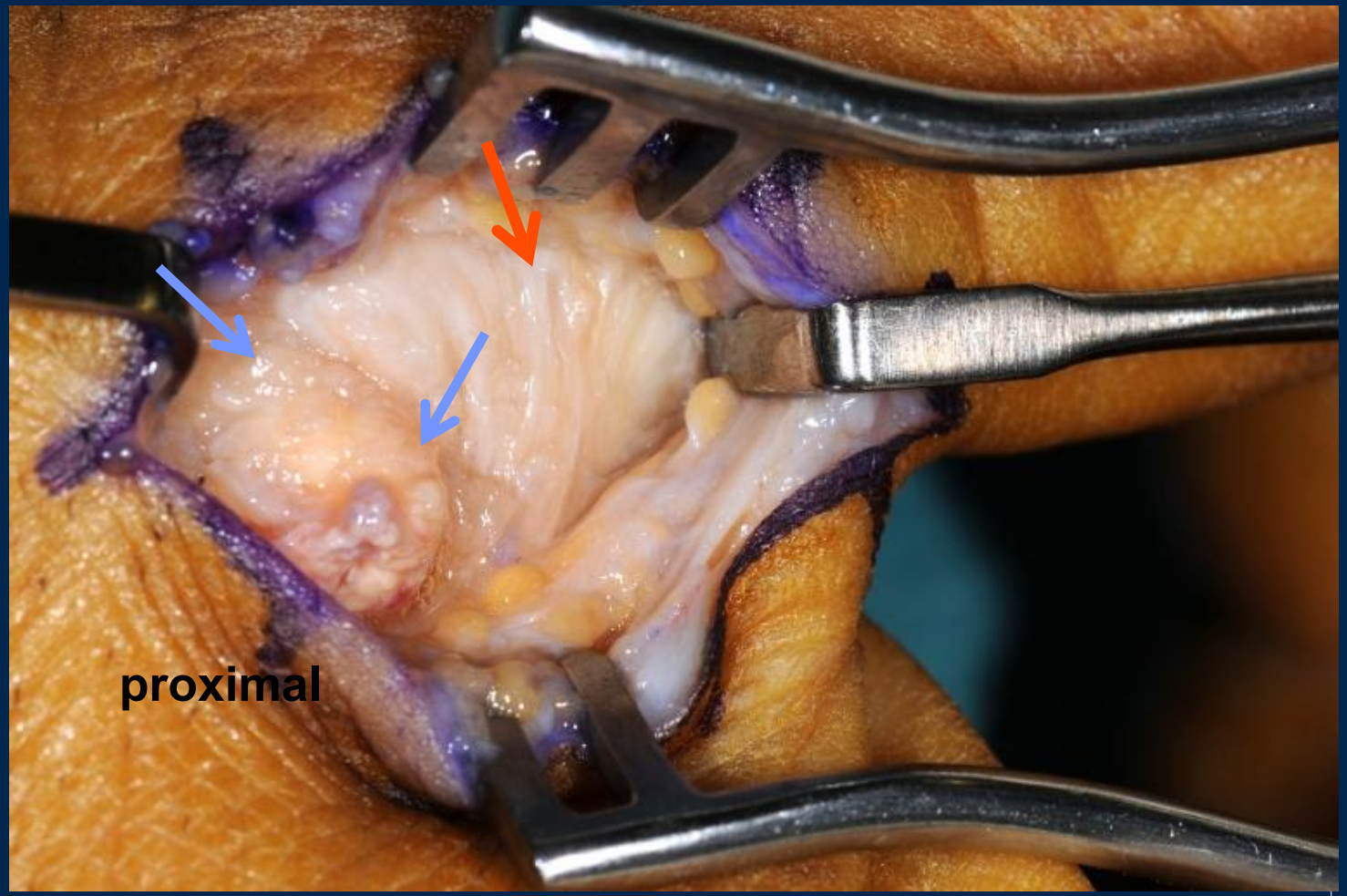

# RUPTUR ULNARES SEITENBAND MP I
## (SKIDAUMEN)



# SEHNEN IM 4./5. STRECKSEHNENFACH

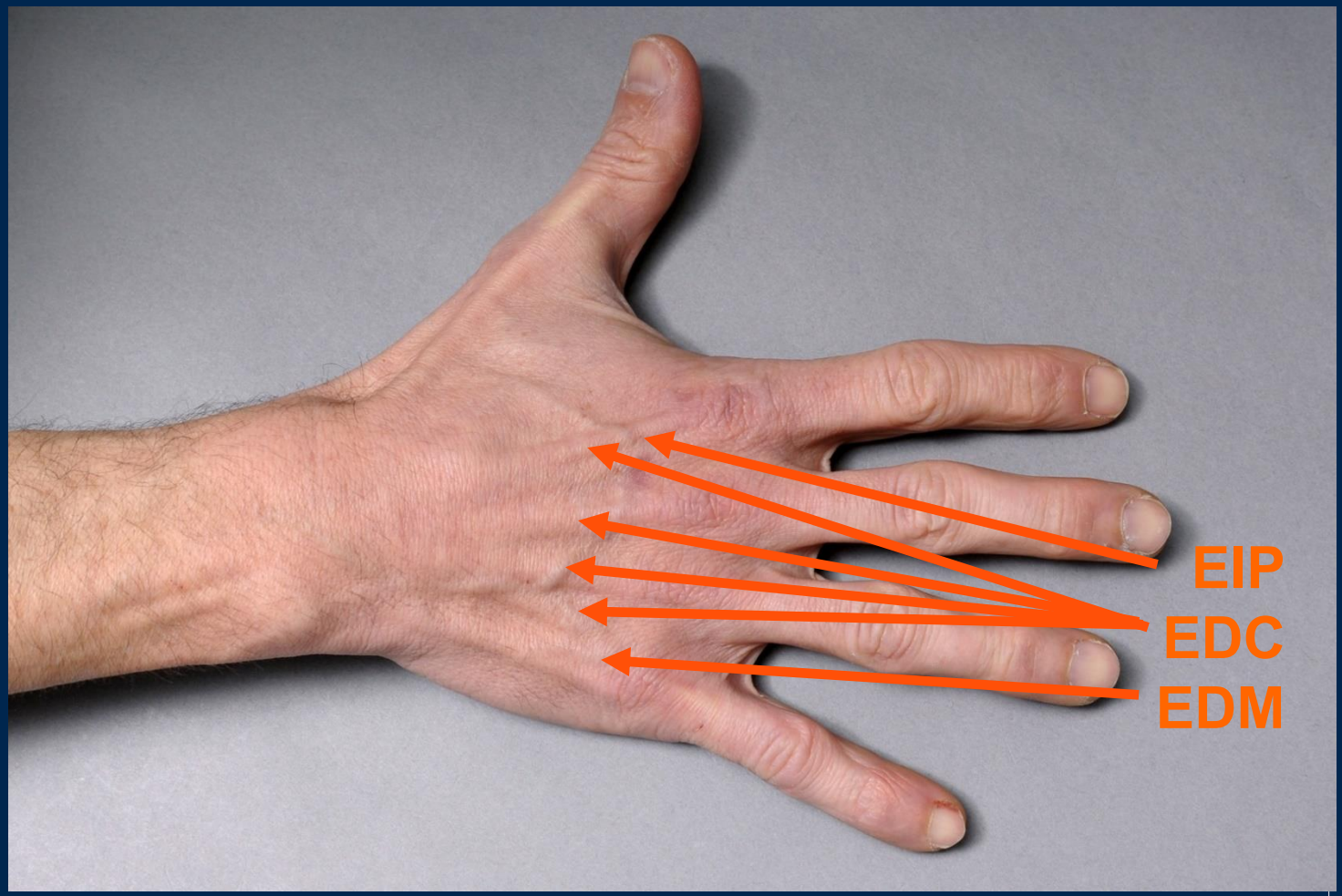

# STRECKAPPARAT FINGER

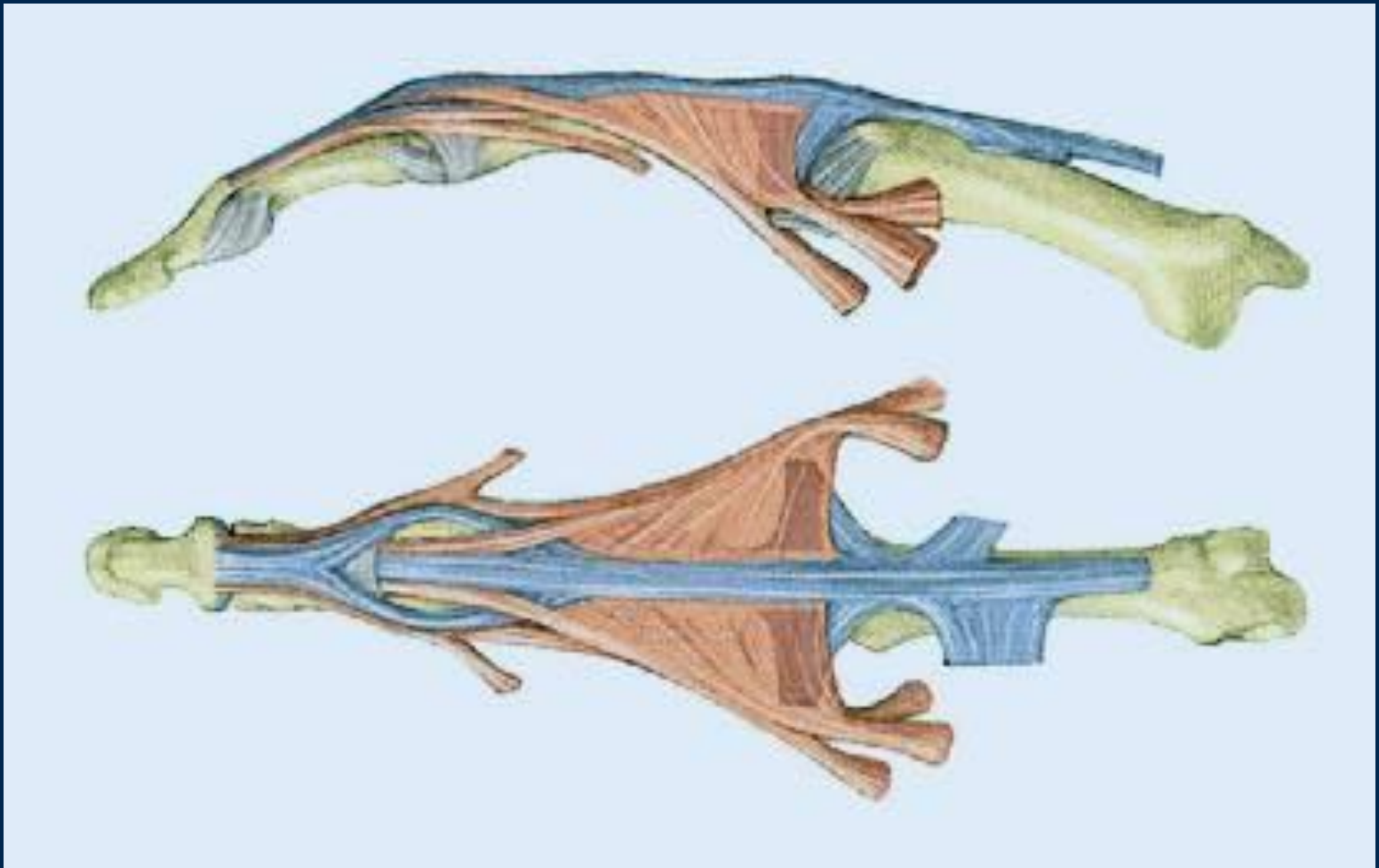

# MALLETFINGER








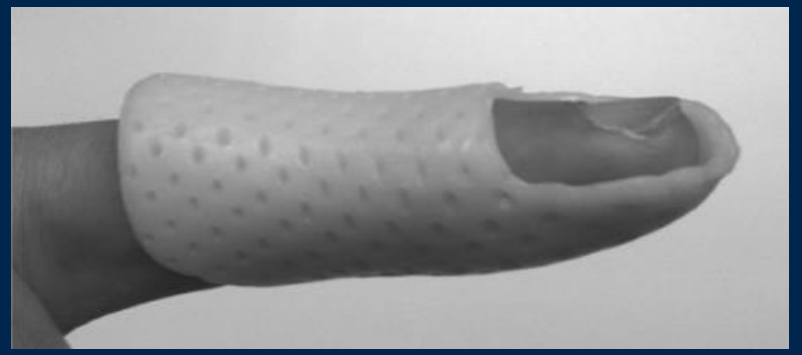

**Konsequent 8 Wochen !**

**STACK'SCHE SCHIENE**

# LANDMARKEN

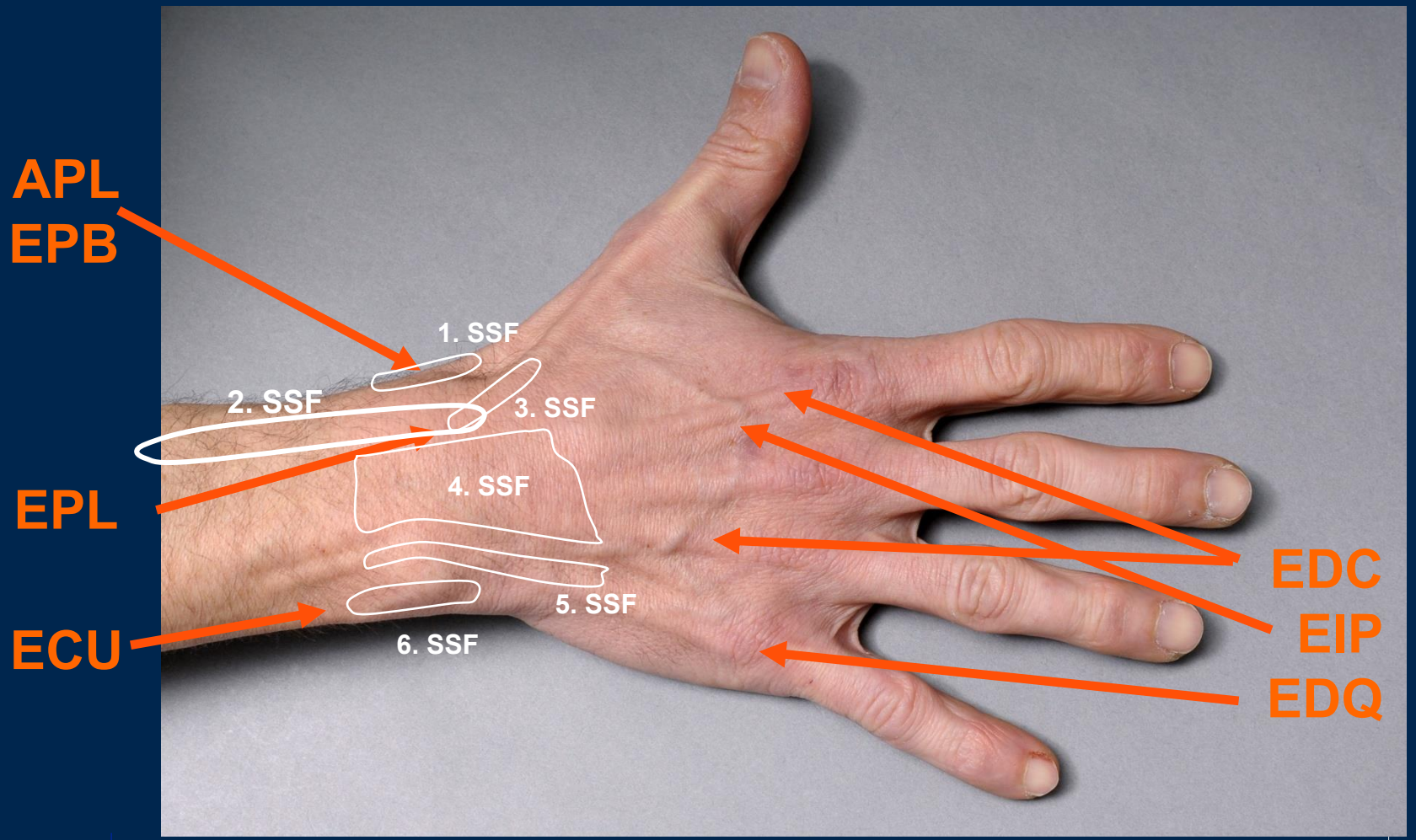

# ECU TENIDINITIS

## ULTRASCHALLGESTEUERTE STEROIDINFILTRATION

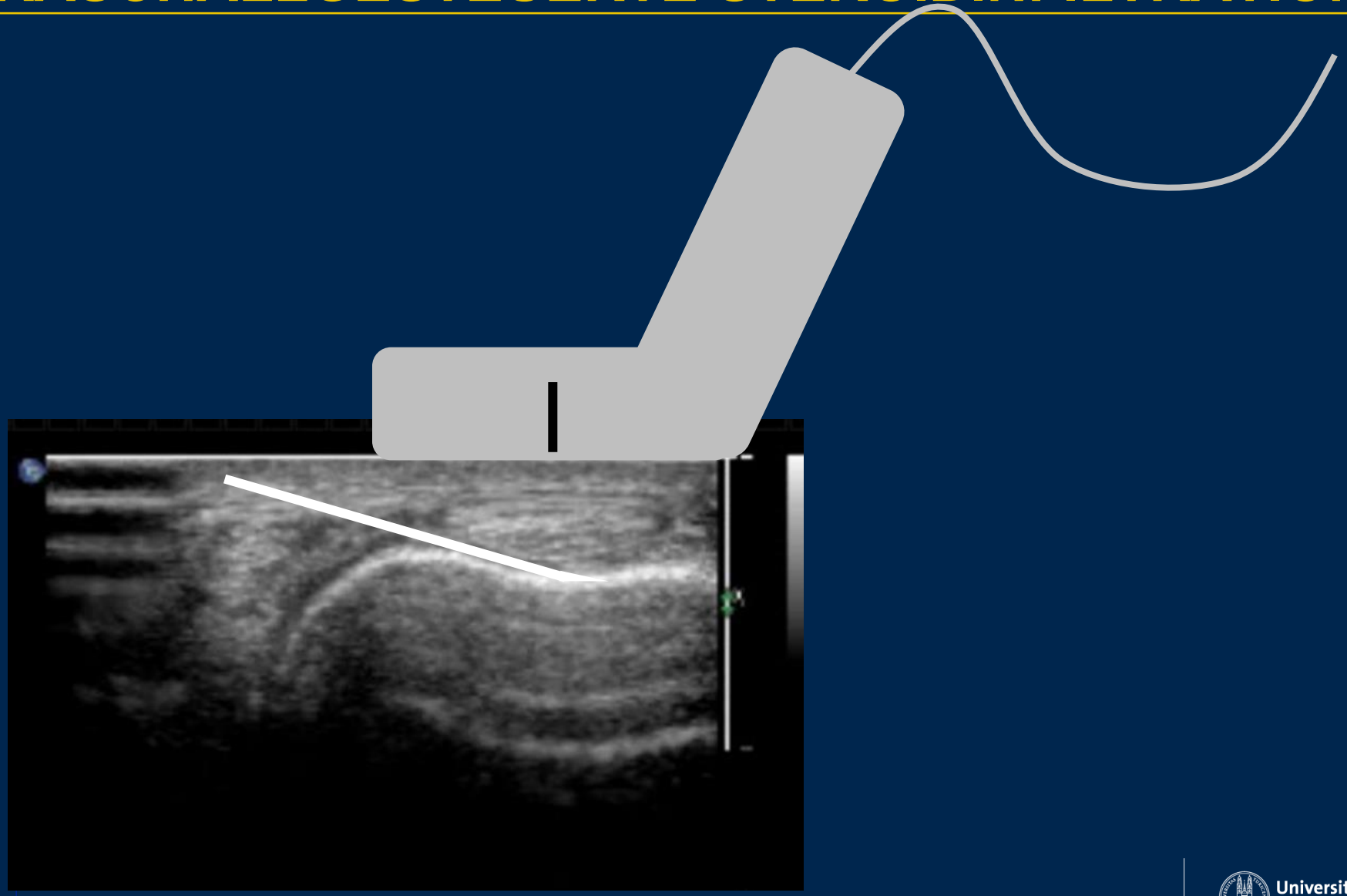

# TENOSYNOVITIS / INSTABILITÄT

## 6. STRECKSEHNENFACH

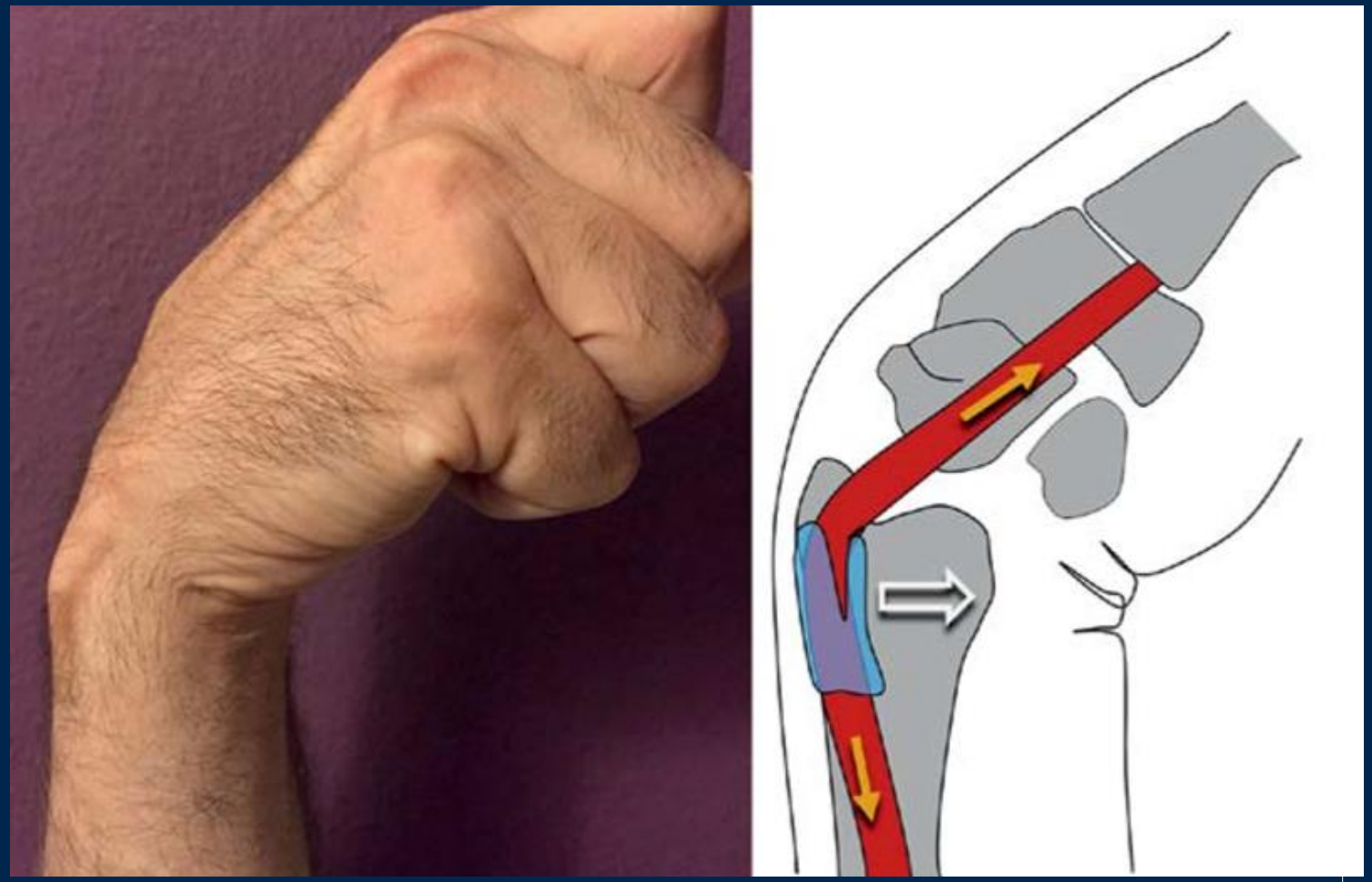

Garcia-Elias M Ha Mi Pla, 2015; 47: 281–289

# INSTABILITÄT 6. SSF: HG FLEX/PRO



# HANDGELENKSGANGLION



# HANDGELENKSGANGLION

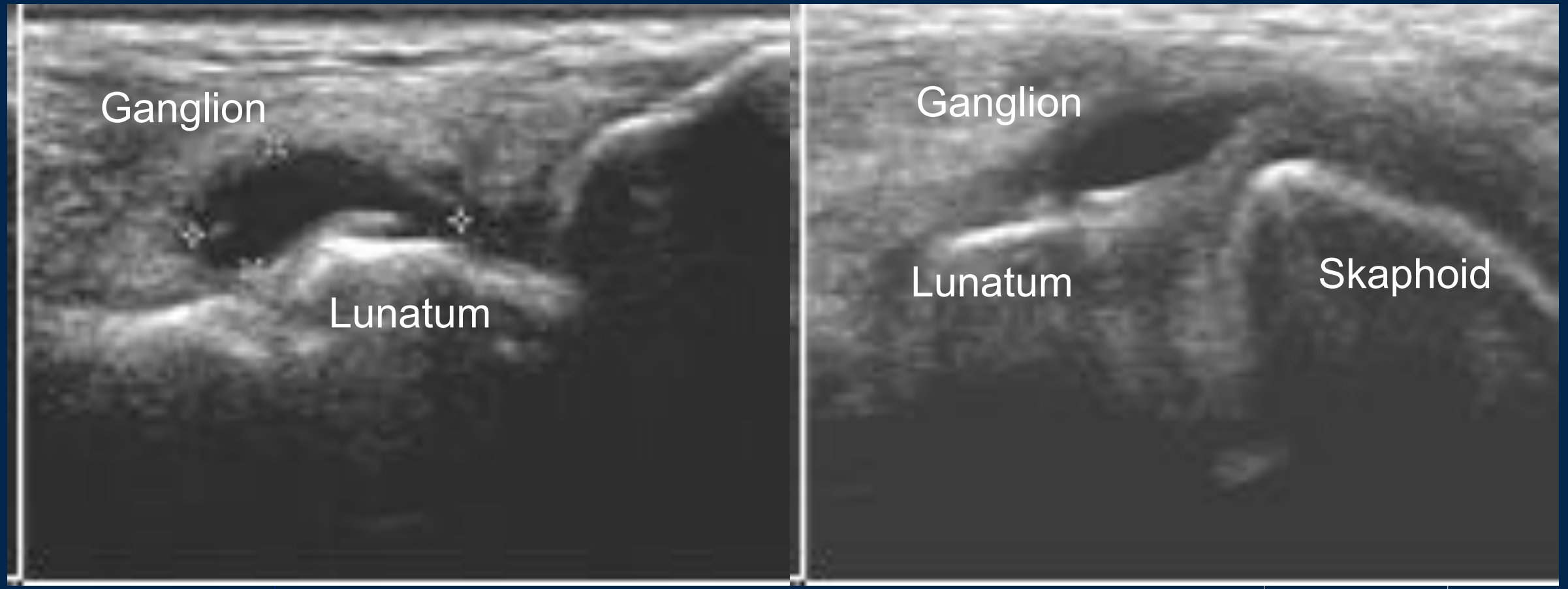

# HANDGELENKSGANGLION
## ULTRASCHALLGESTEUERTE PUNKTION/INFILTRATION

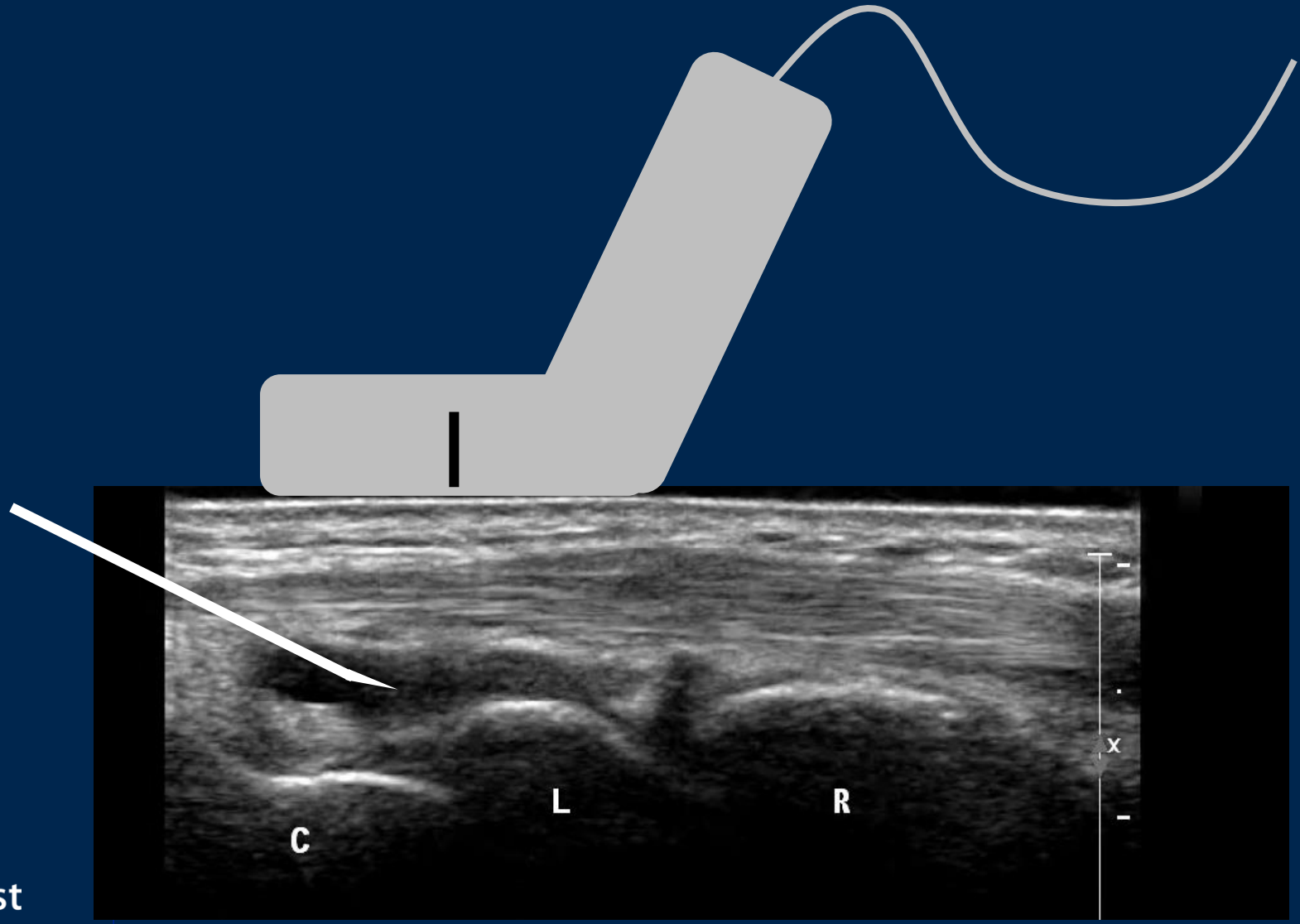

# HANDGELENKSGANGLION



# MUKOIDZYSTE



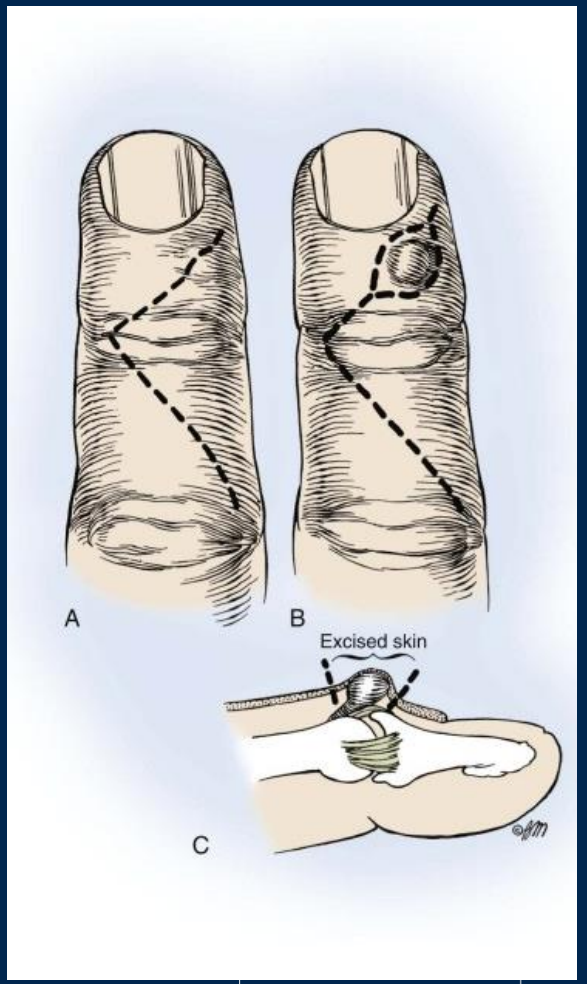

# POLYARTHROSE
## KLINIK



# POLYARTHROSE
## RÖNTGENBILD



# POLYARTHROSE
## INFILTRATION PIP UND DIP GELENK

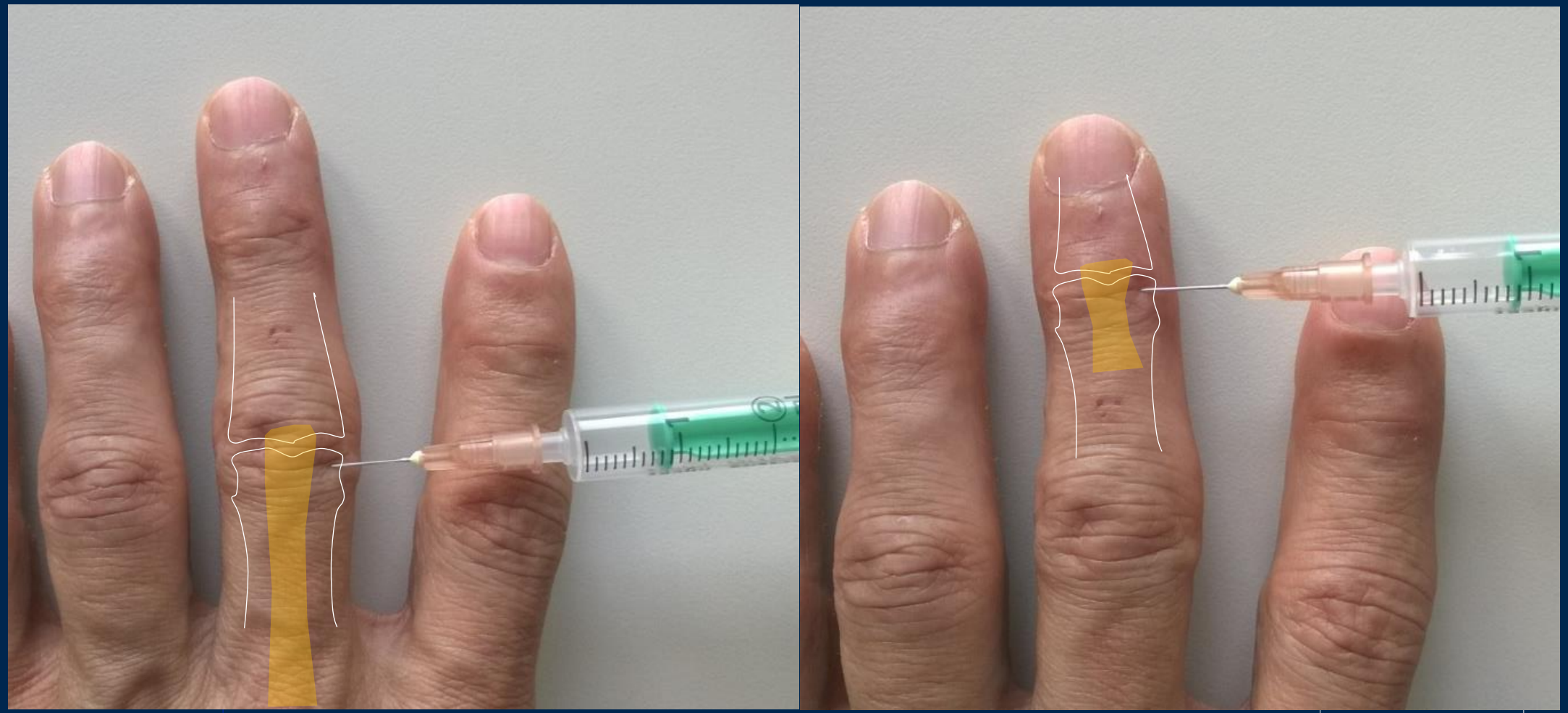

# POLYARTHROSE
## OPERATION

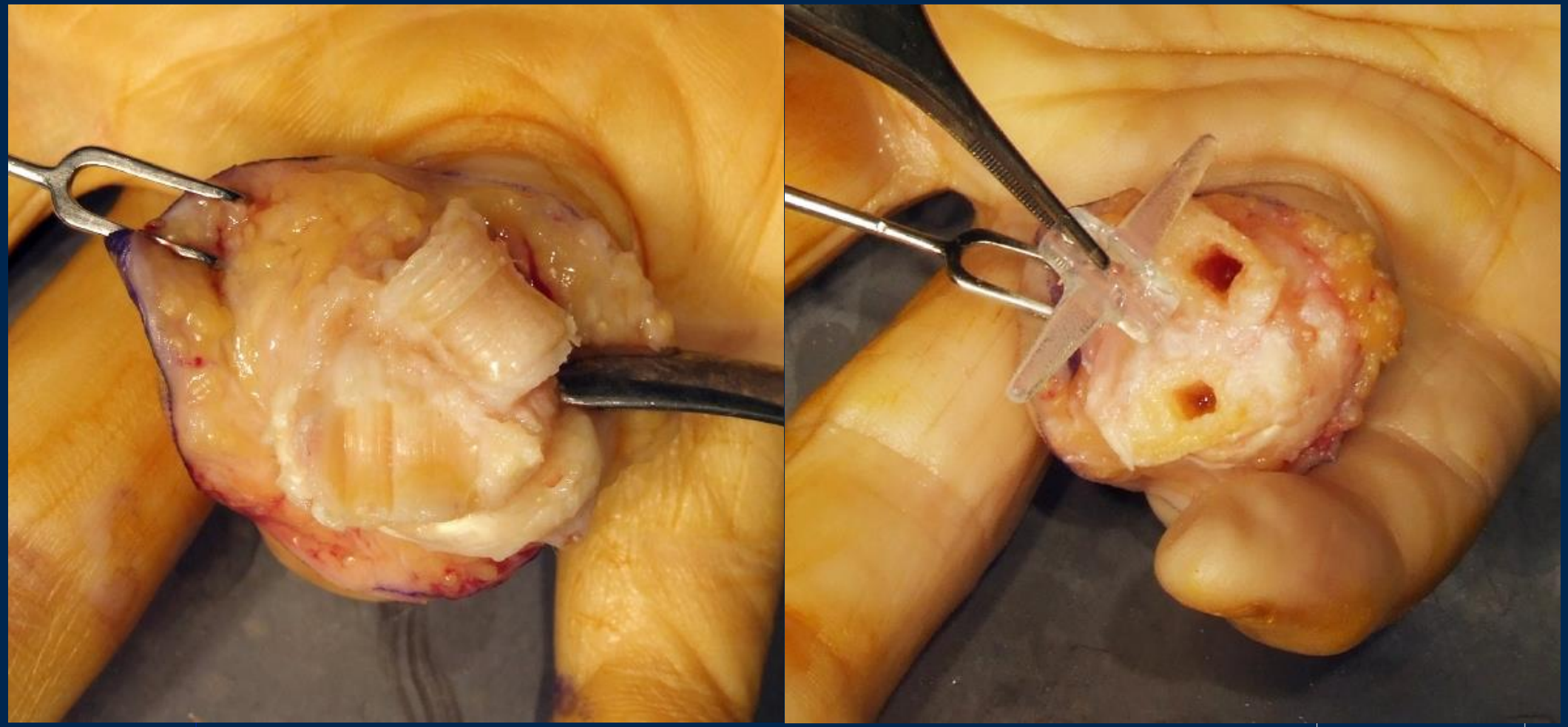

# POLYARTHROSE
## RÖNTGENBILD POSTOPERATIV

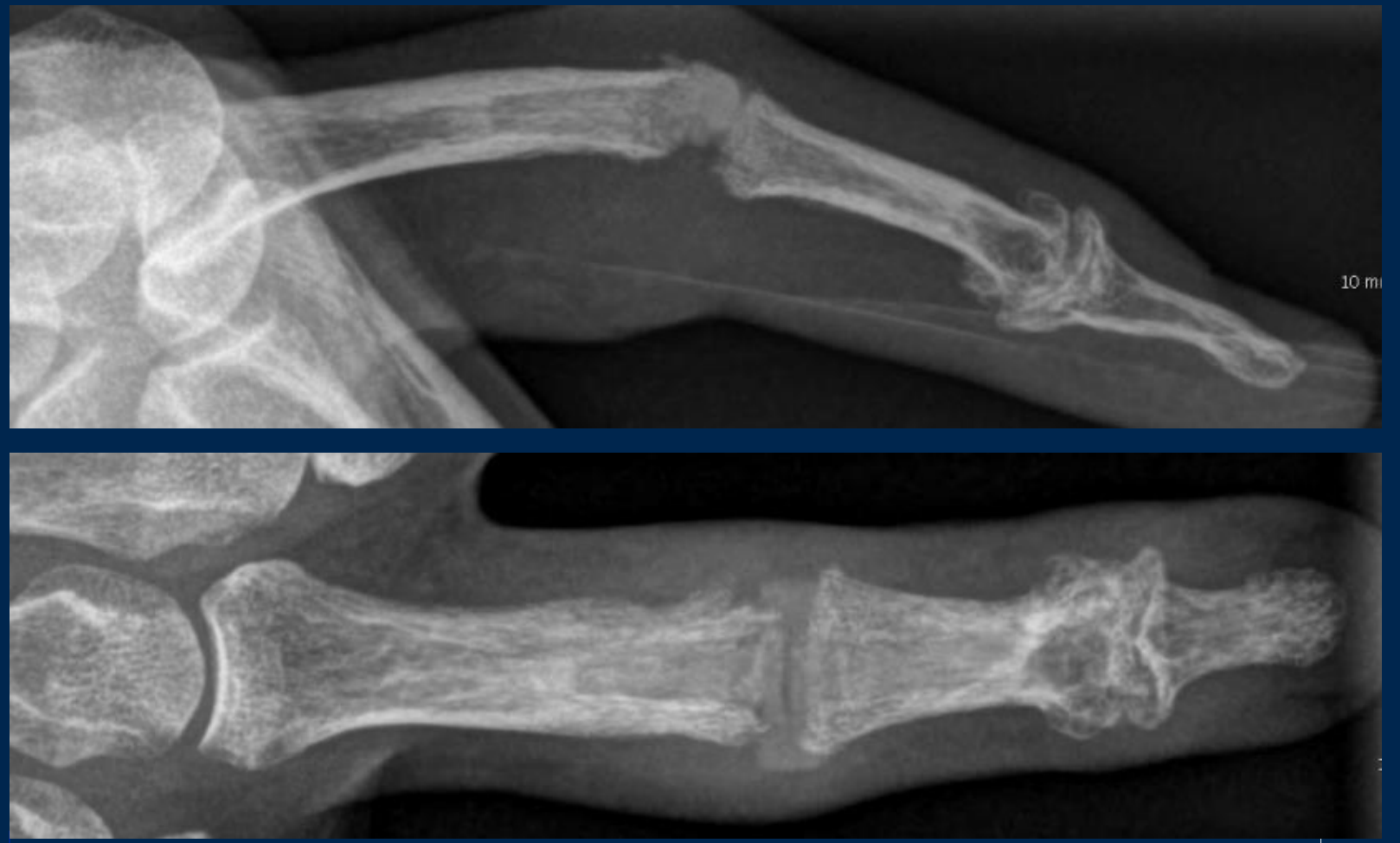

# POLYARTHROSE
## RÖNTGENBILD POSTOPERATIV

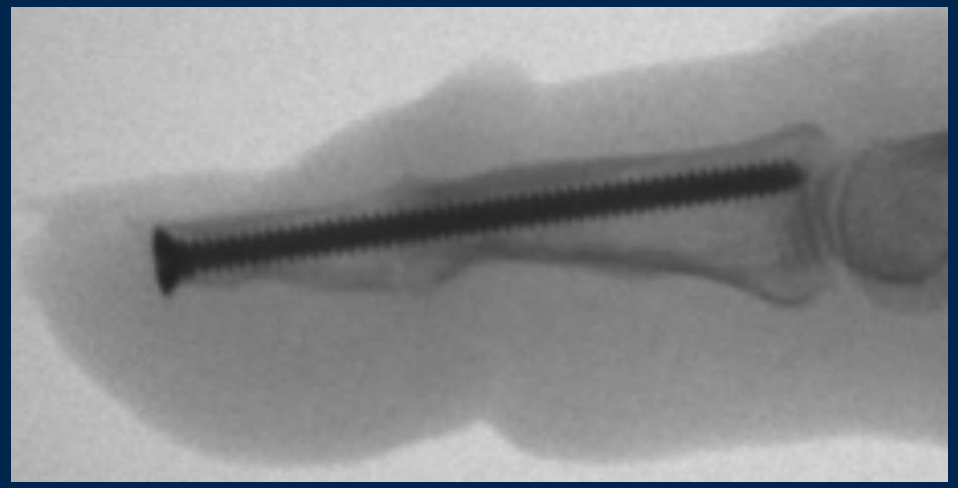

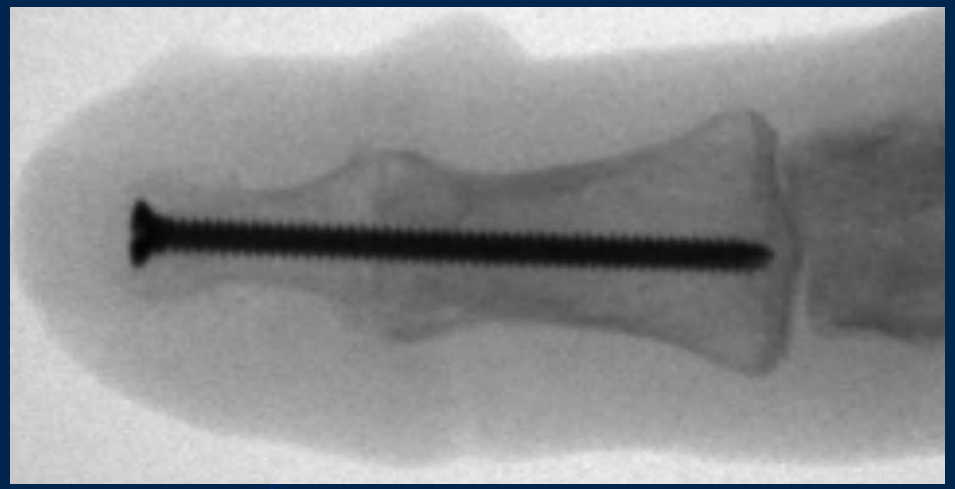

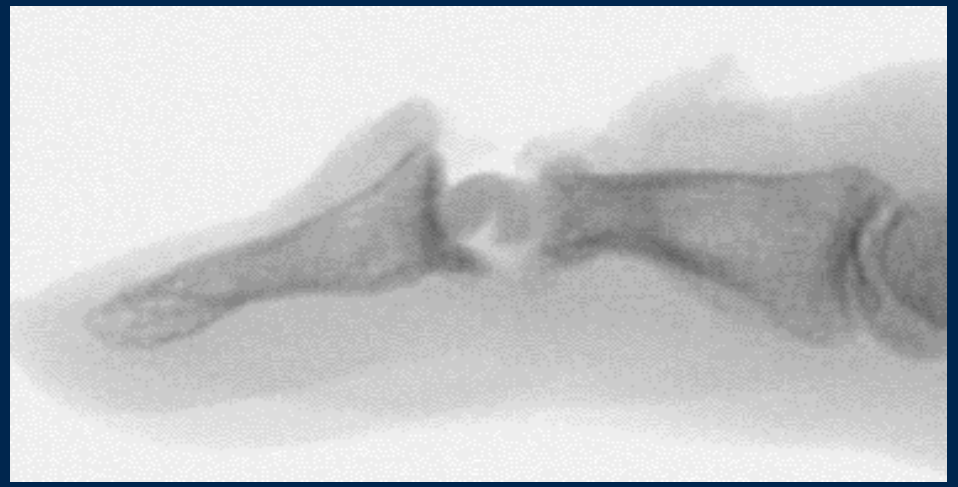



# LANDMARKEN

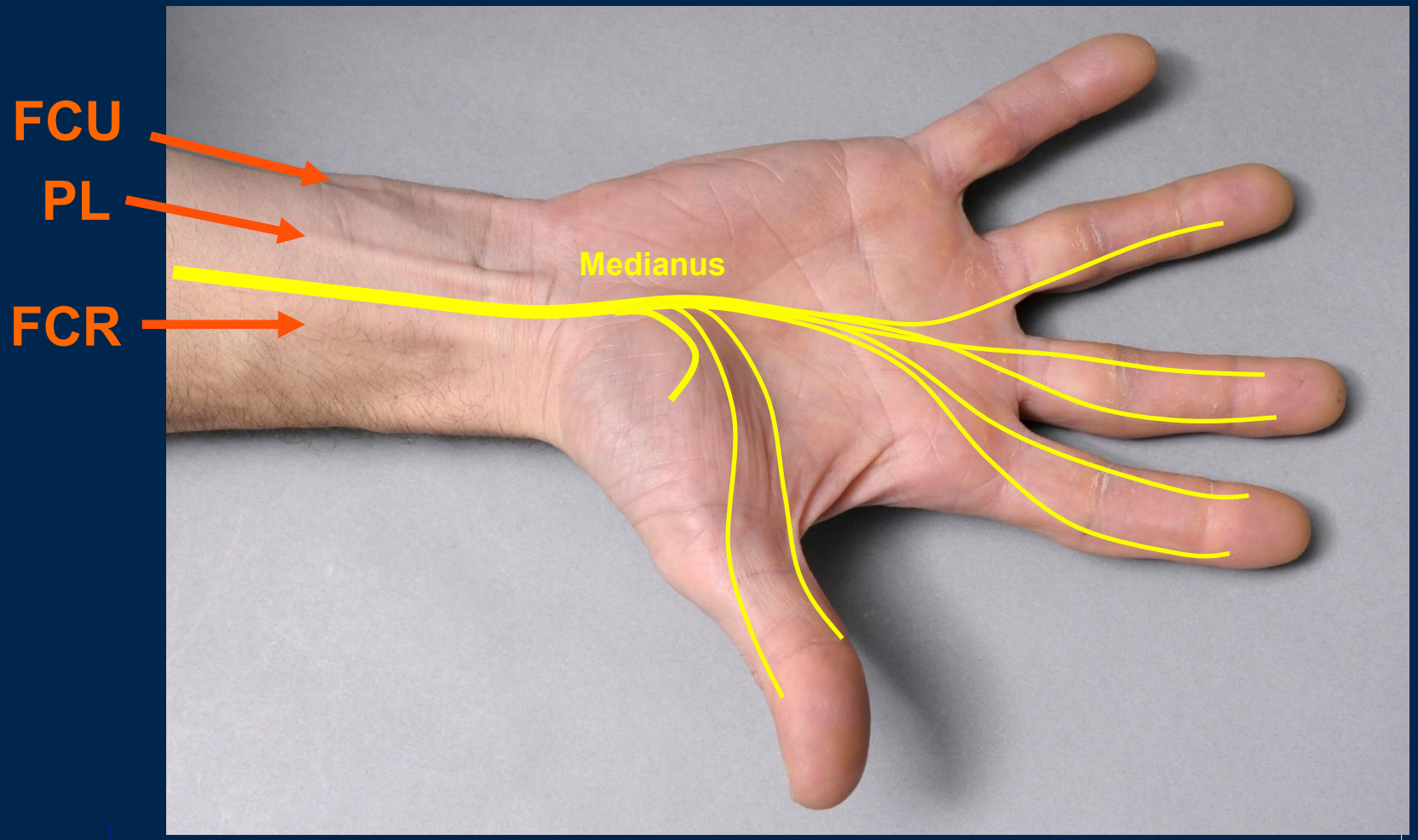

# KARPALTUNNELSYNDROM
## TINEL ZEICHEN

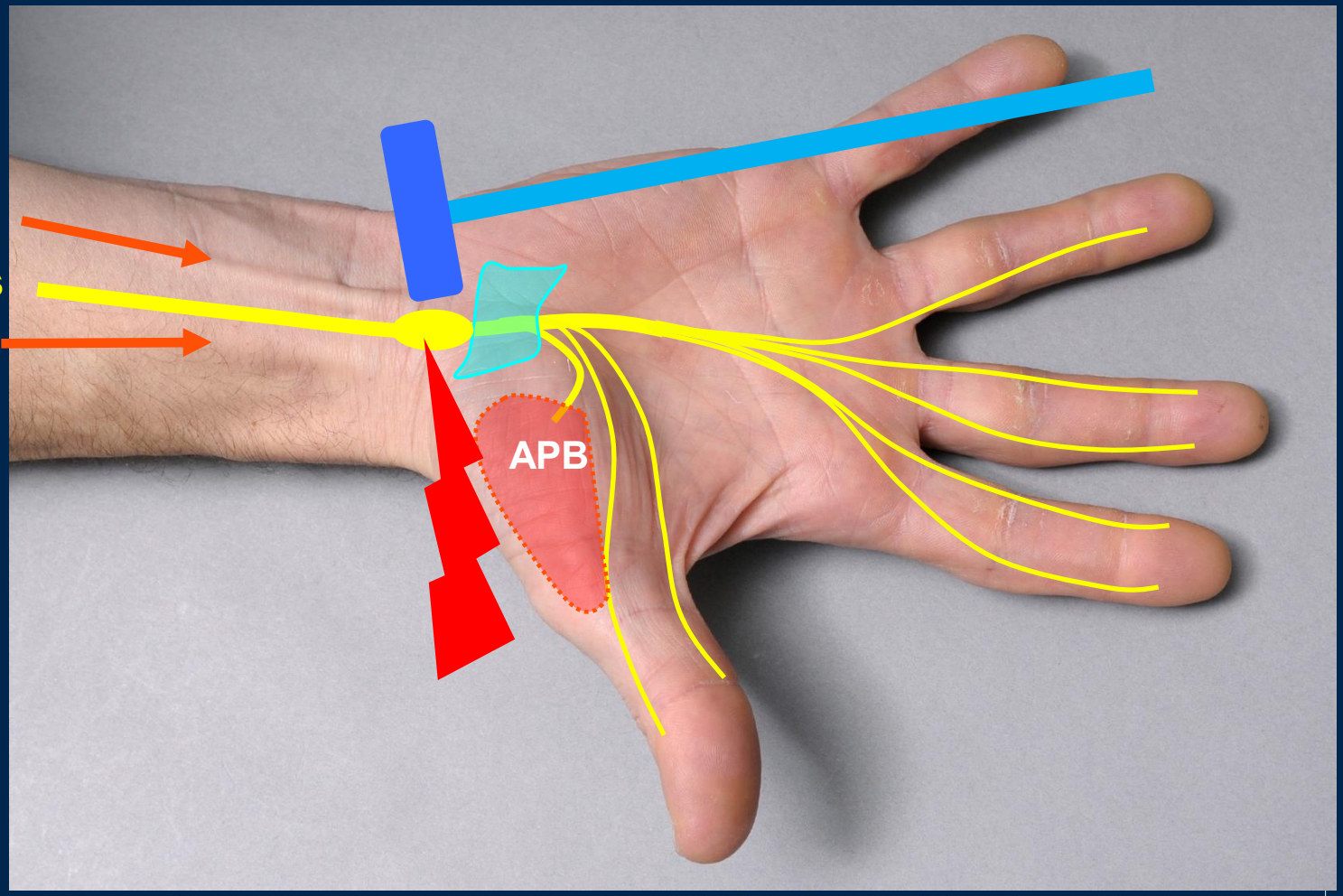

# KARPALTUNNELSYNDROM
## TINEL ZEICHEN

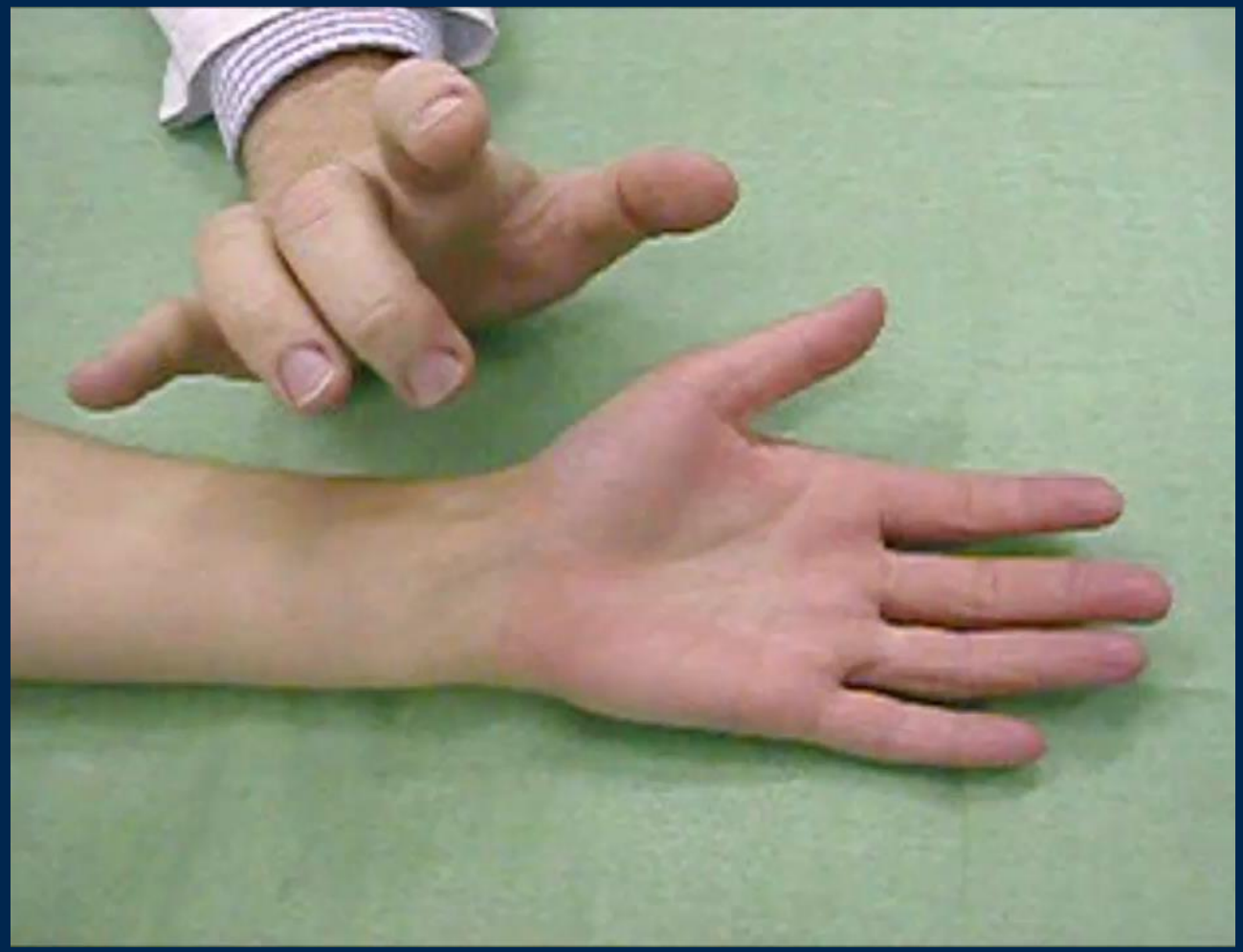

# KARPALTUNNELSYNDROM
## PHALEN TEST, N. MEDIANUS KOMRESSIONSTEST

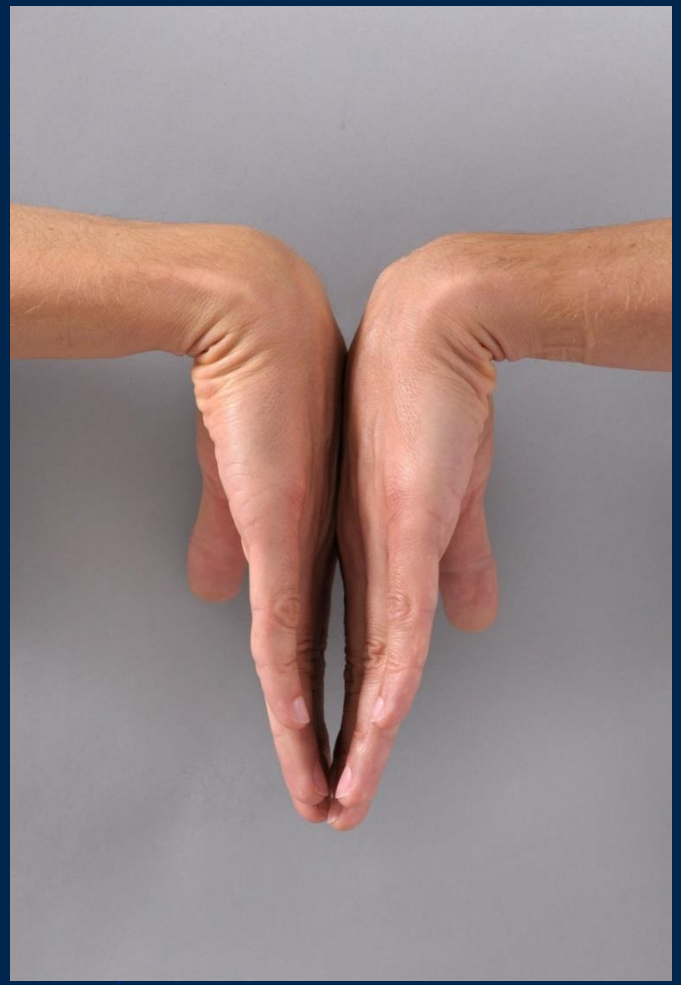

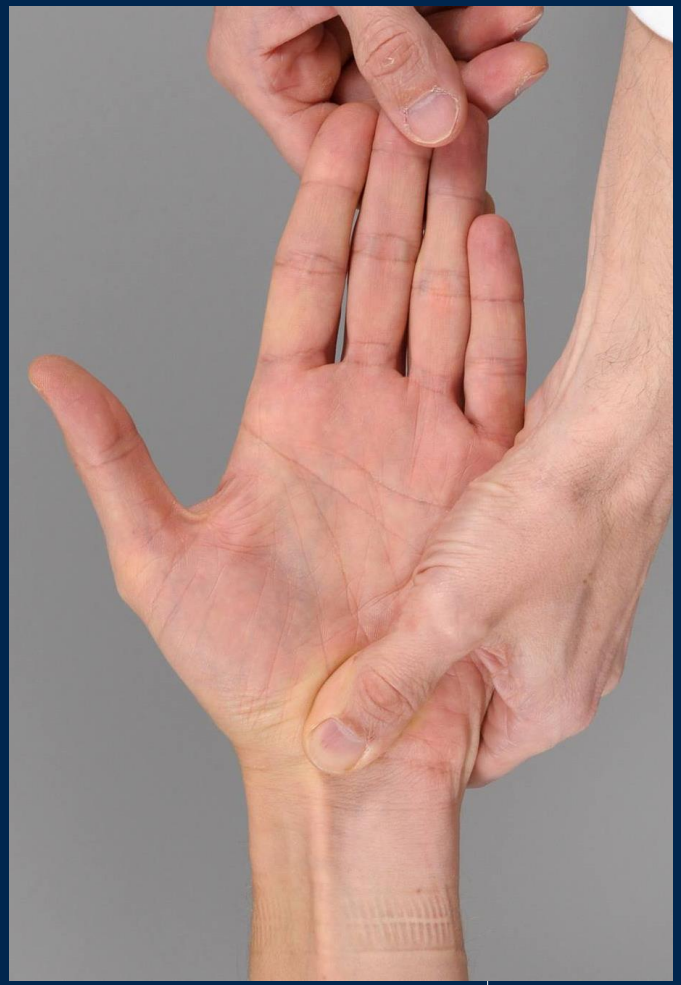

# KARPALTUNNELSYNDROM
## SENSIBILITÄT

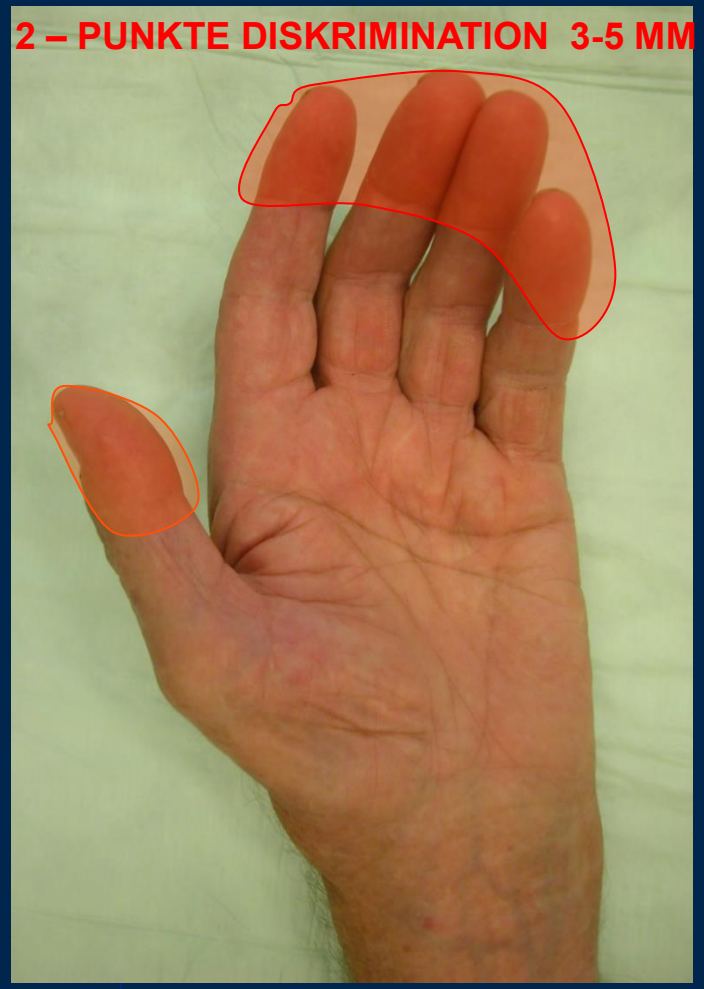




# KARPALTUNNELSYNDROM
## SONOGRAPHIE

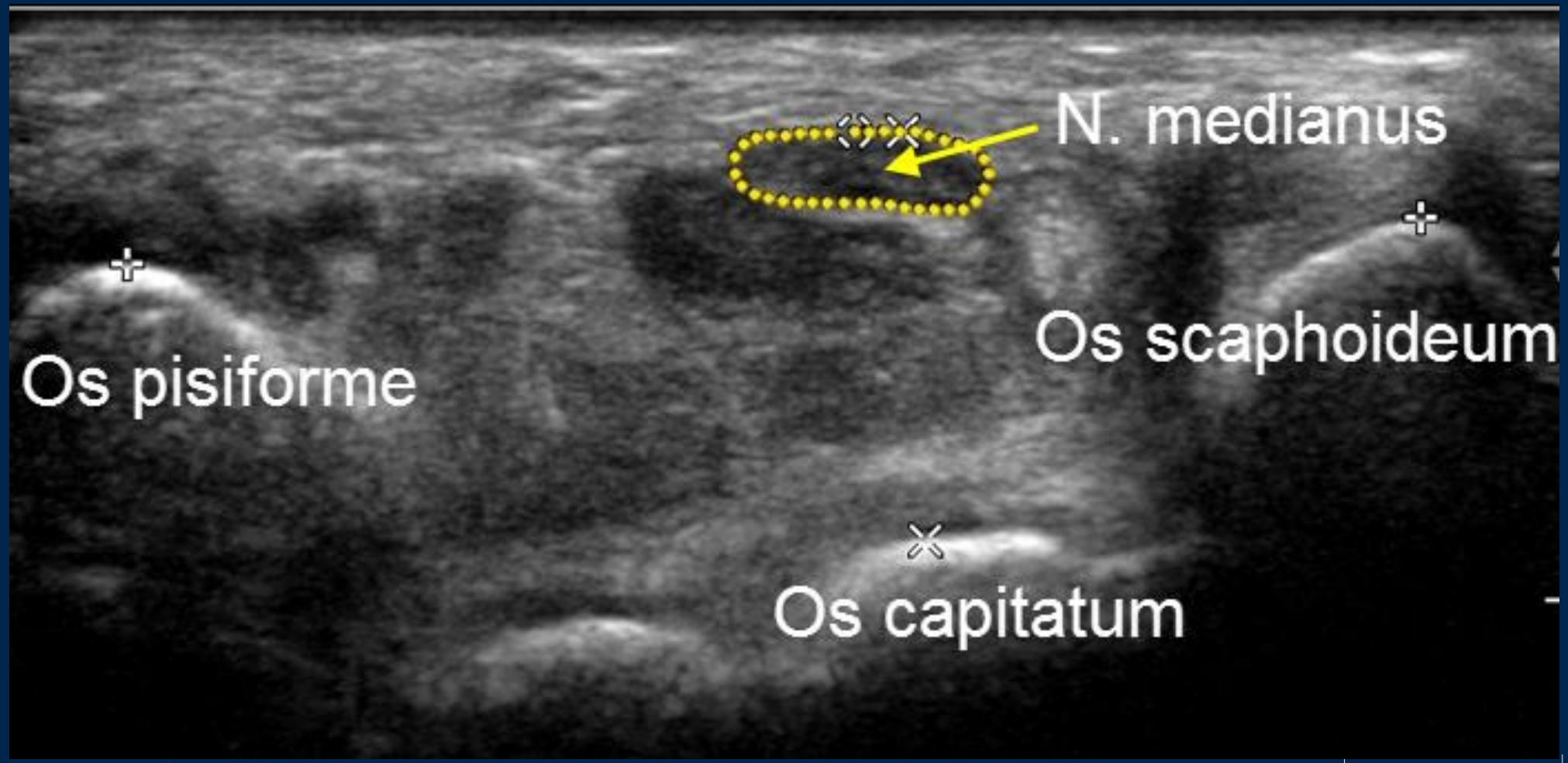

# KARPALTUNNELSYNDROM
## NACHTLAGERUNGSSCHIENE



# KARPALTUNNELSYNDROM
## INFILTRATION STEROID

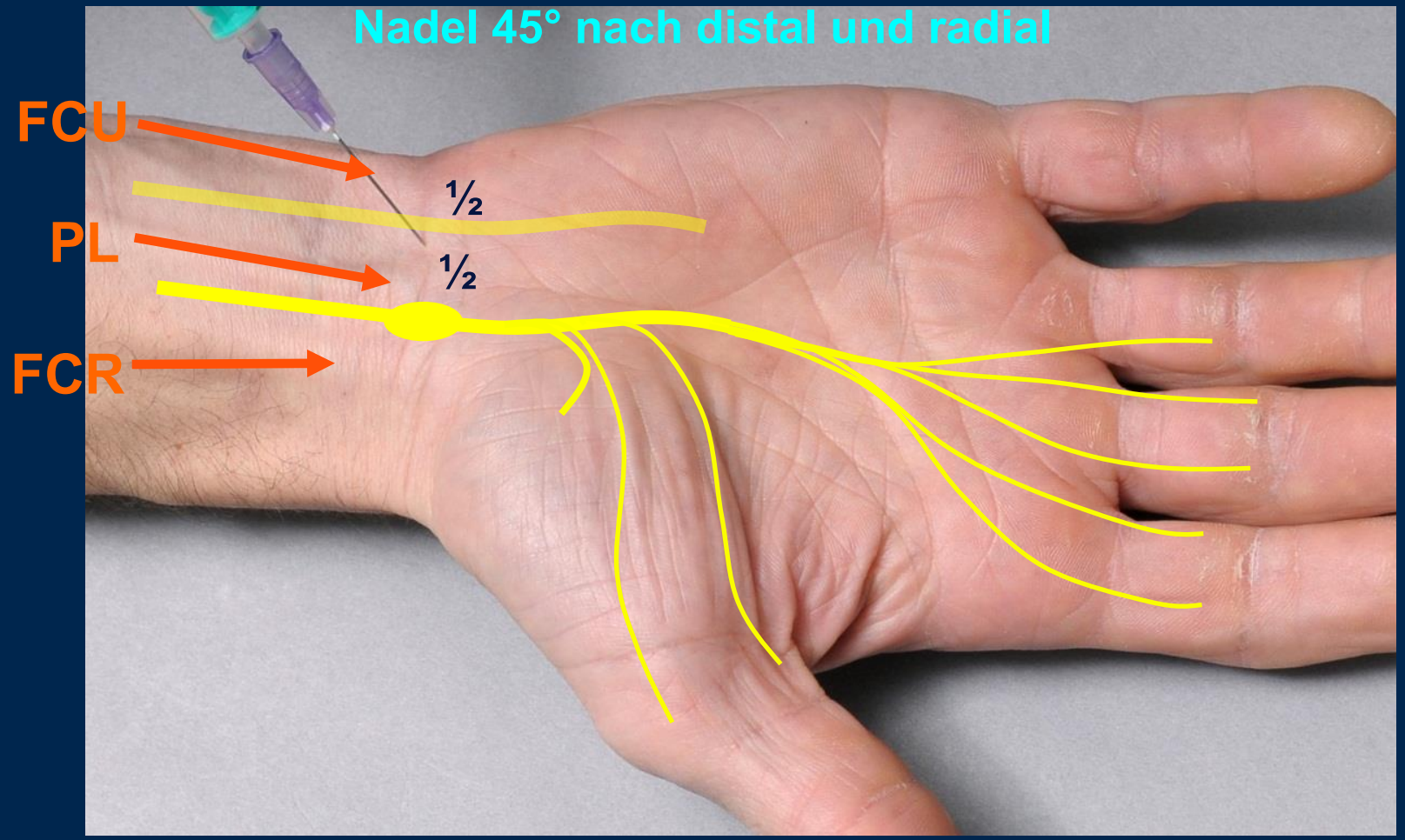

# KARPALTUNNELSYNDROM
## OPERATION

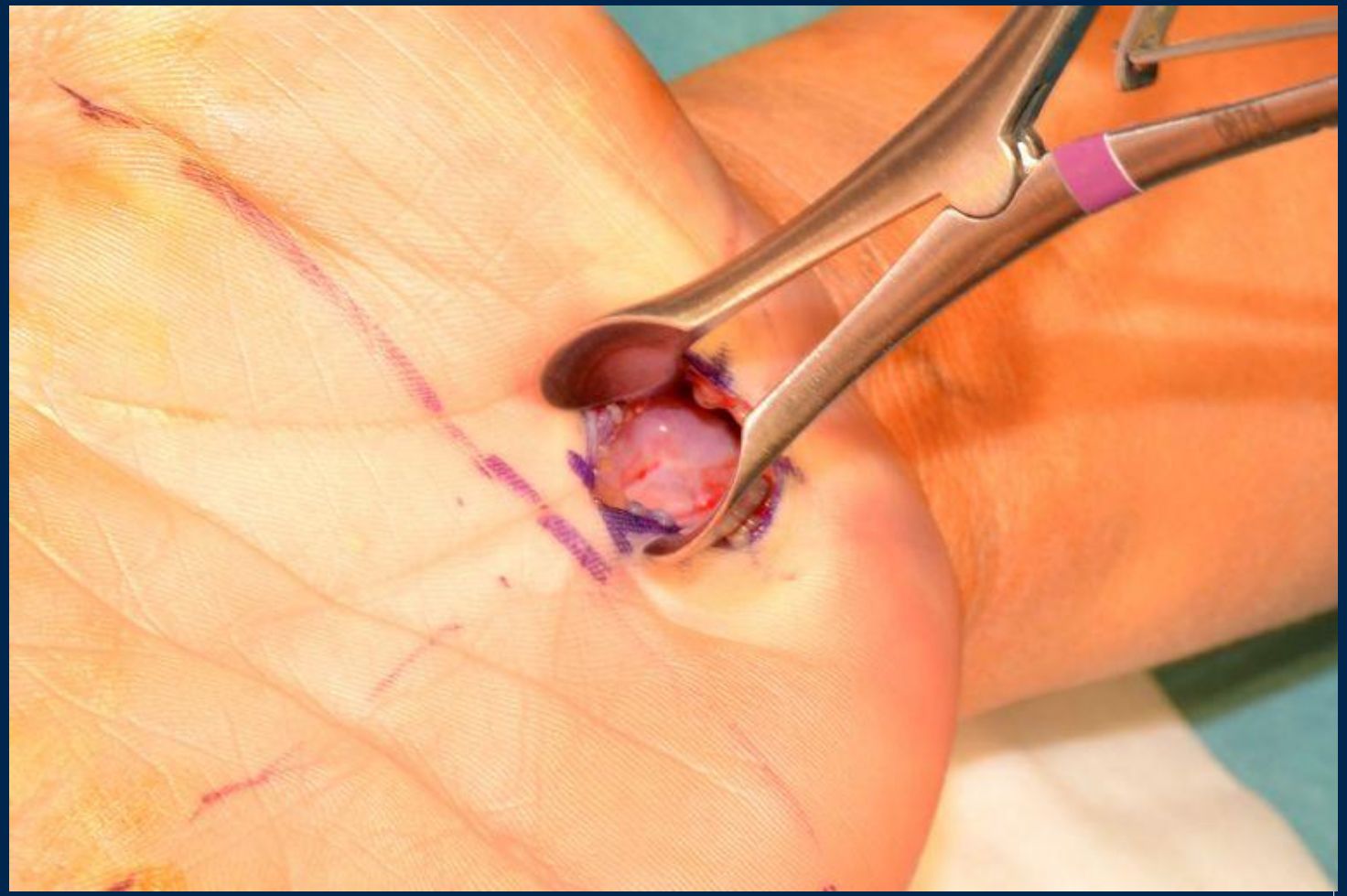

# KARPALTUNNELSYNDROM

## OPERATION OFFEN

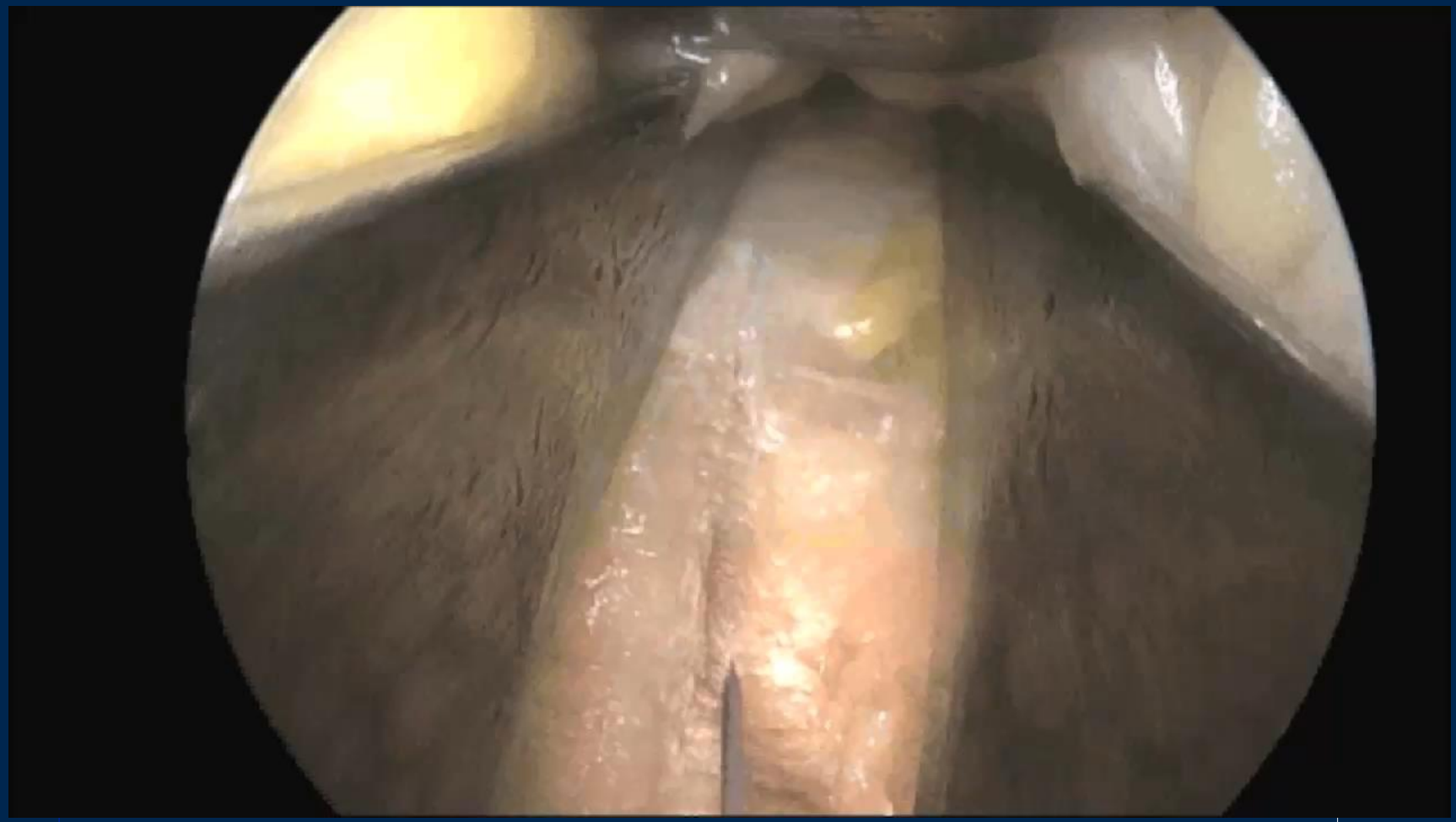

# KARPALTUNNELSYNDROM

## OPERATION ENDOSKOPISCH



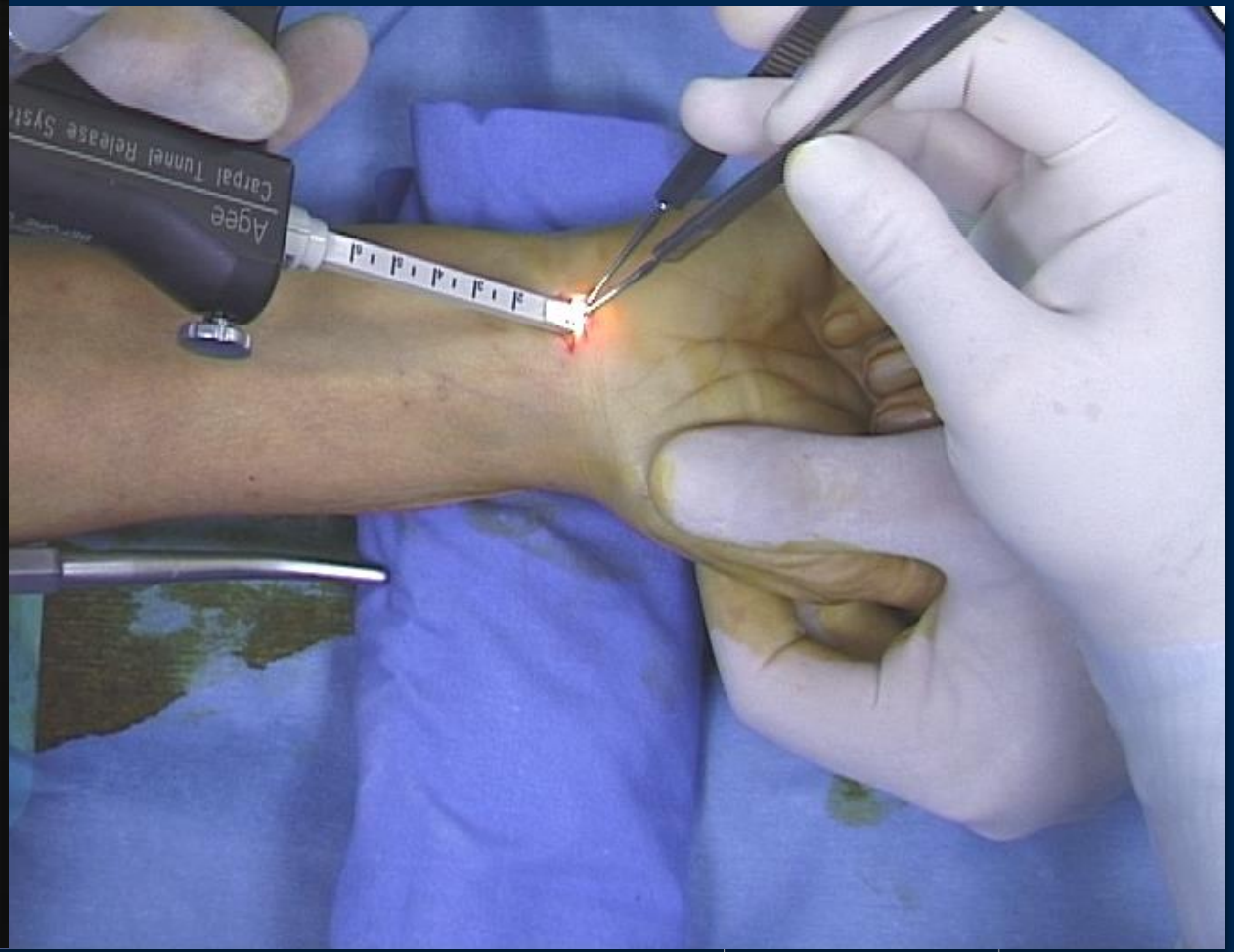

# KARPALTUNNELSYNDROM
## OPERATION ULTRASCHALLGESTEUERT

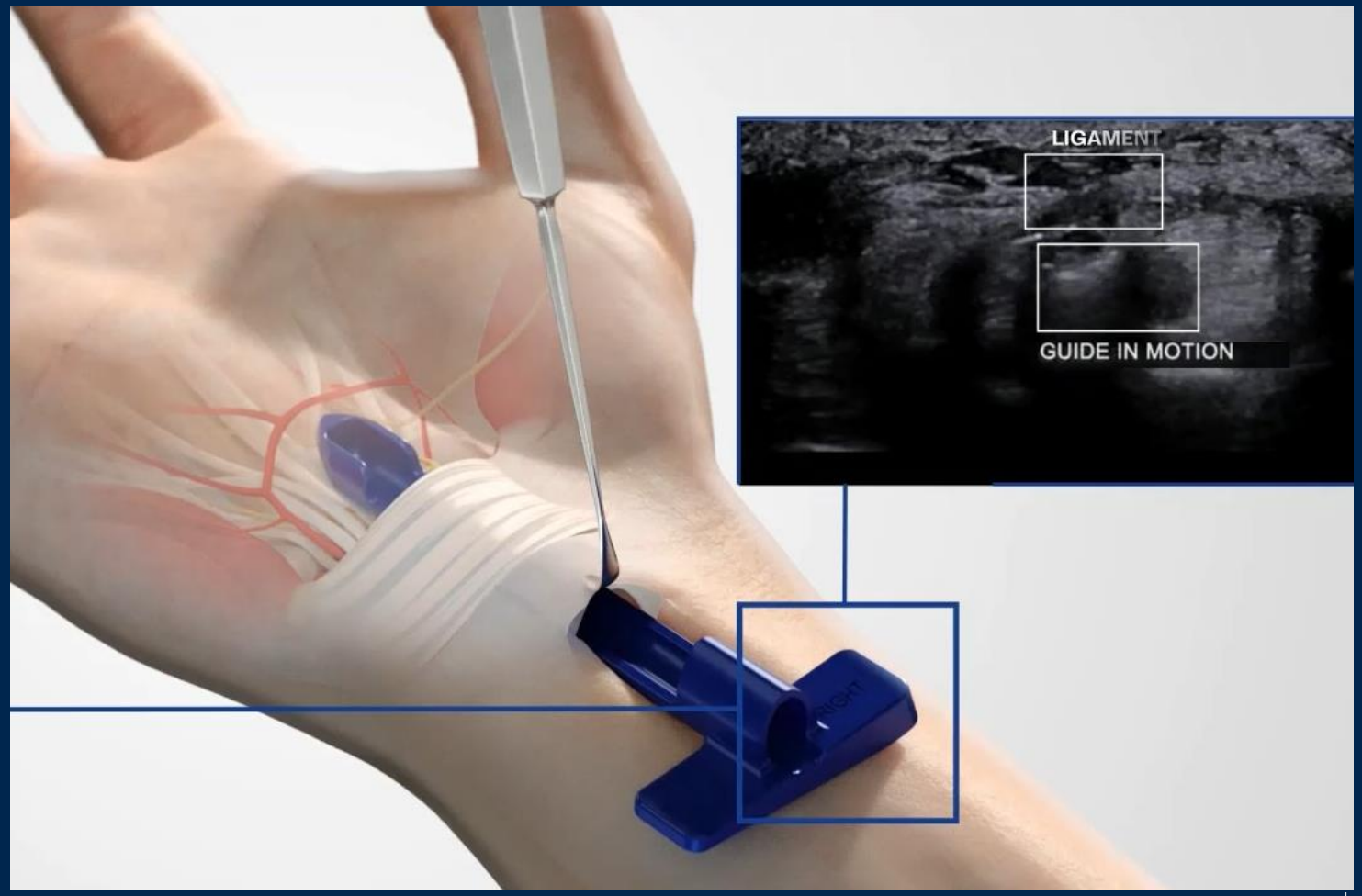

# LANDMARKEN

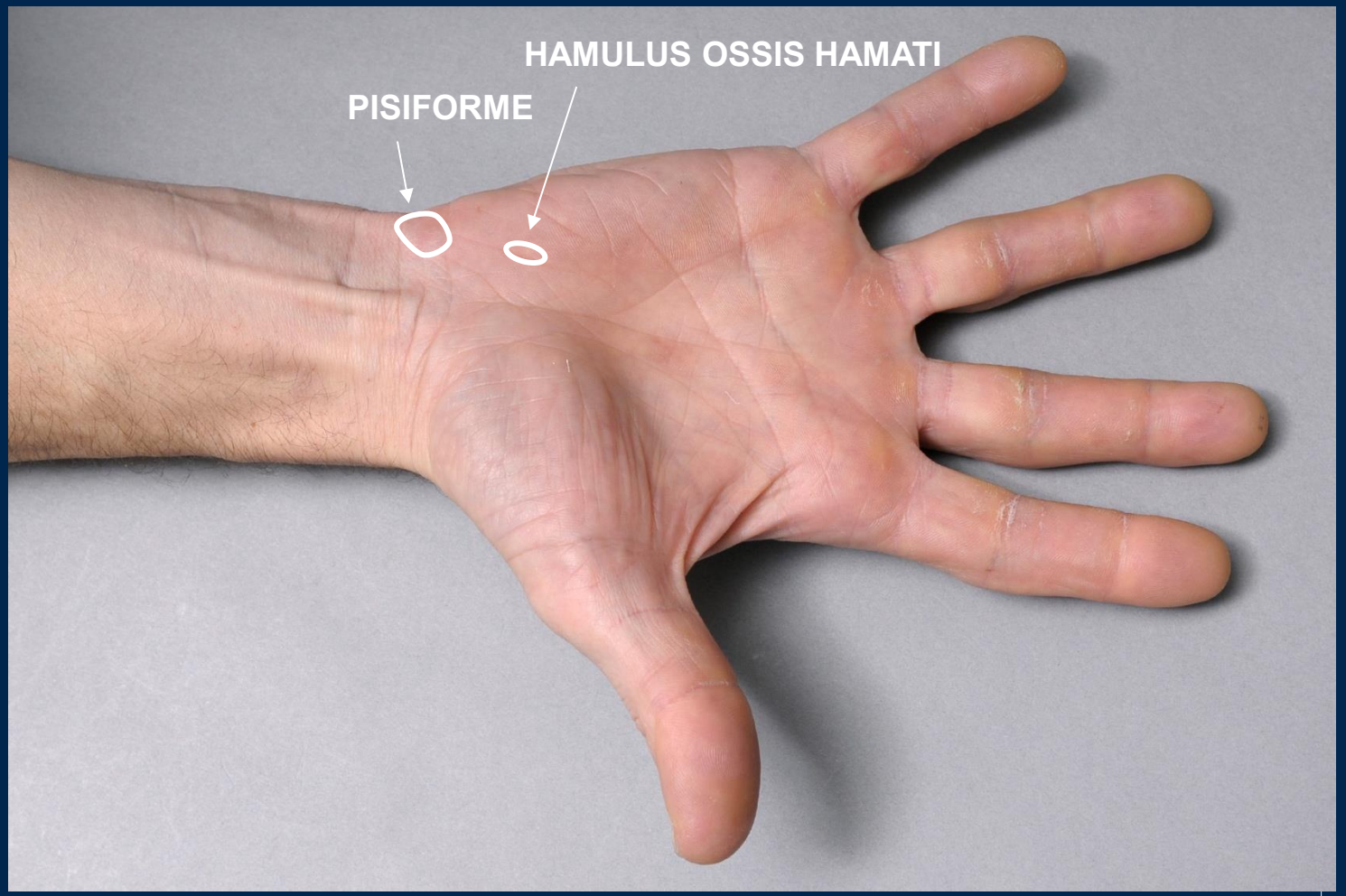

# UNTERSUCHUNG
## FLEXOR DIGITORUM PROFUNDUS



# UNTERSUCHUNG

## FLEXOR DIGITORUM SUPERFICIALIS

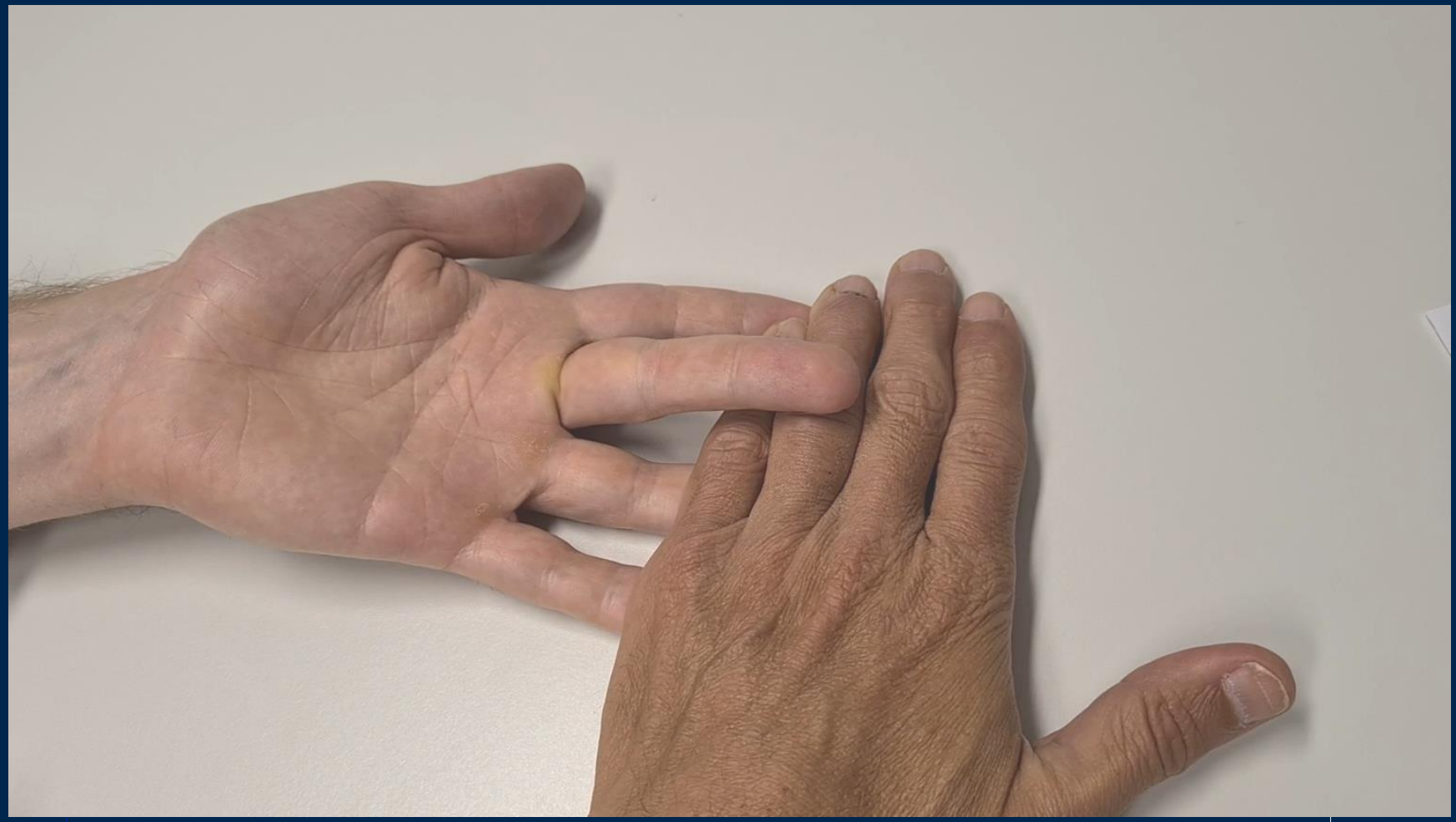

# LANDMARKEN

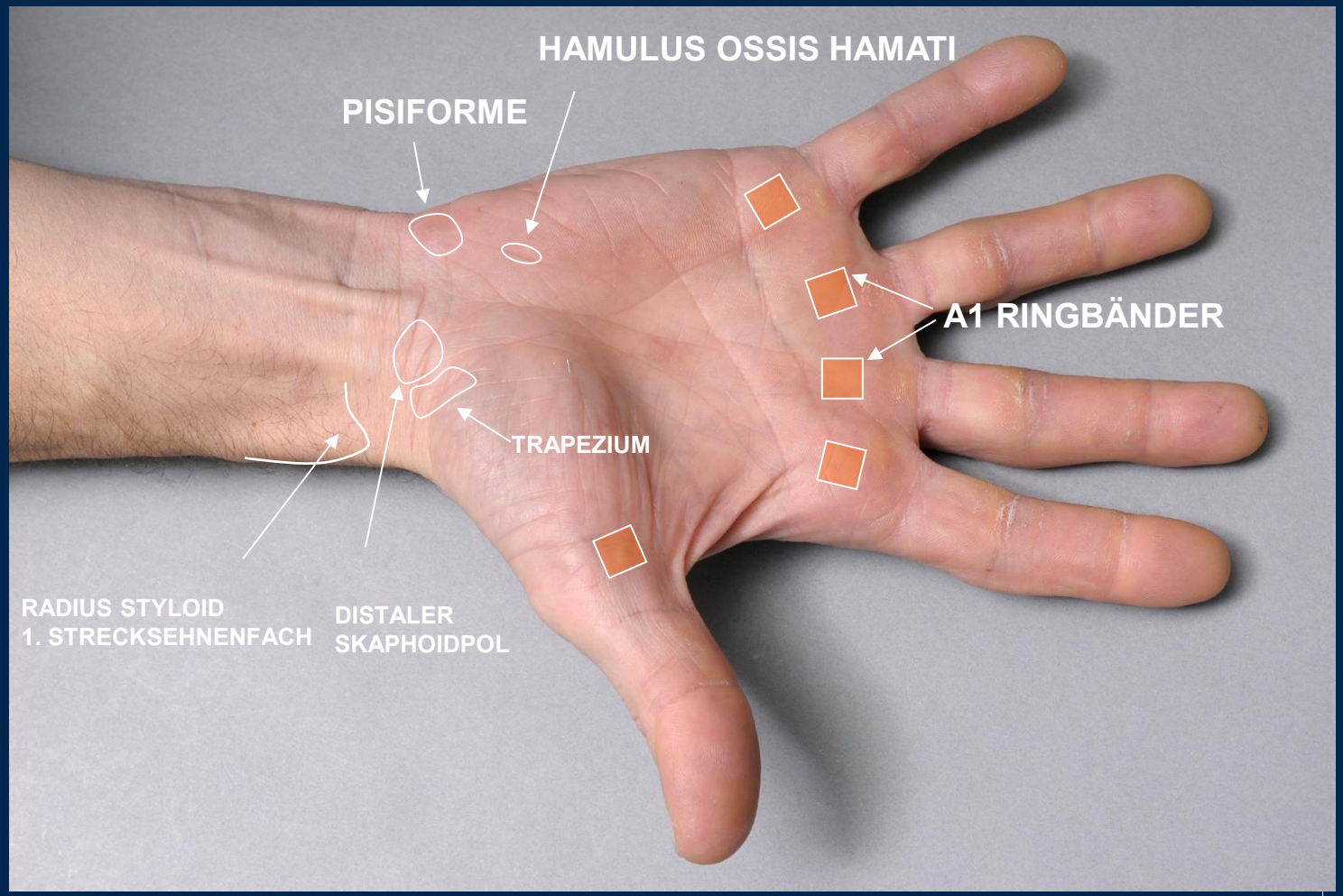
HAMULUS OSSIS HAMATI
PISIFORME
A1 RINGBÄNDER
TRAPEZIUM
RADIUS STYLOID
1. STRECKSEHNENFACH
DISTALER
SKAPHOIDPOL

# TENDOVAGINITIS STENOSANS
## PATHOGENESE

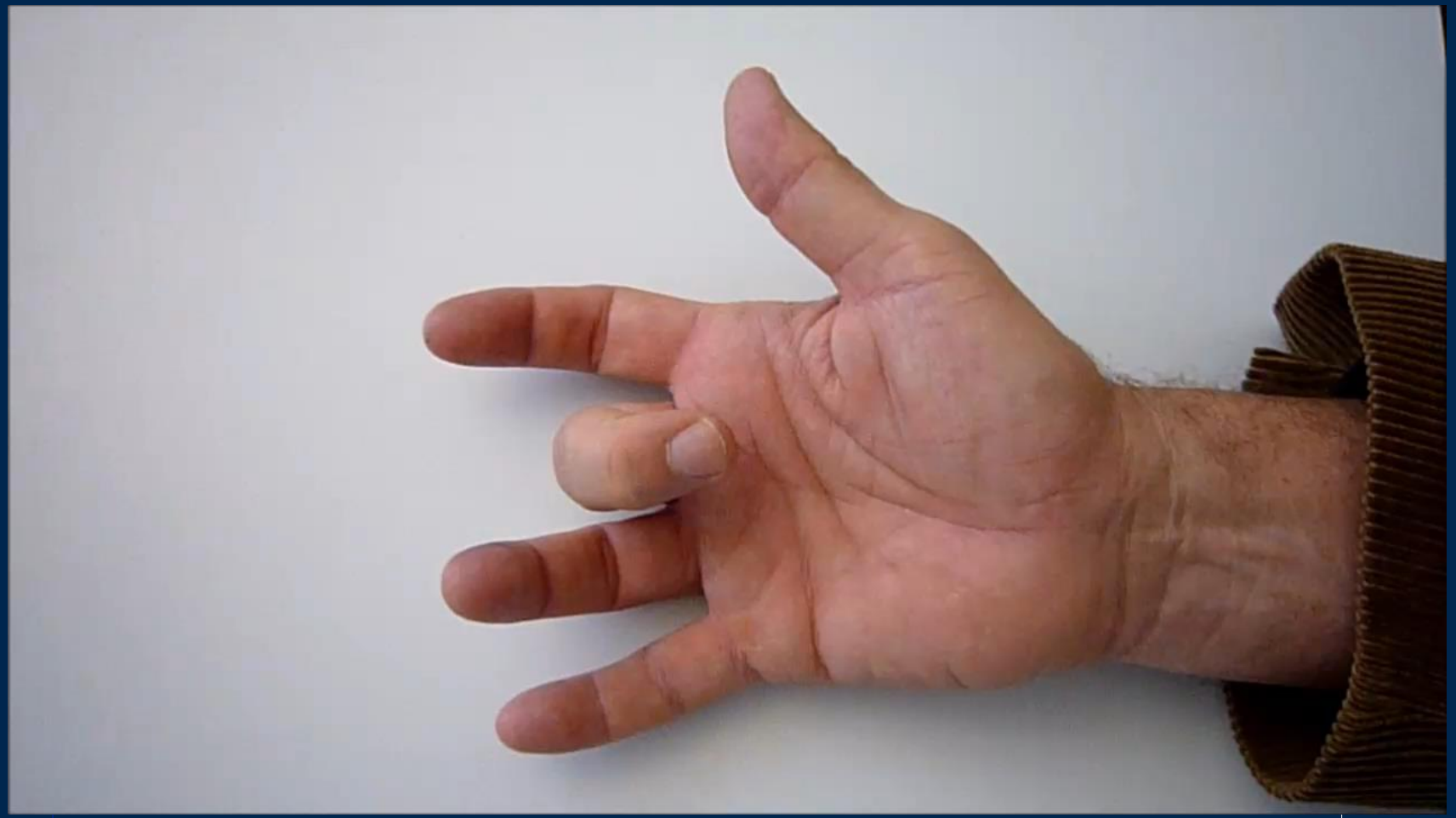

# TENDOVAGINITIS STENOSANS
## PATHOGENESE

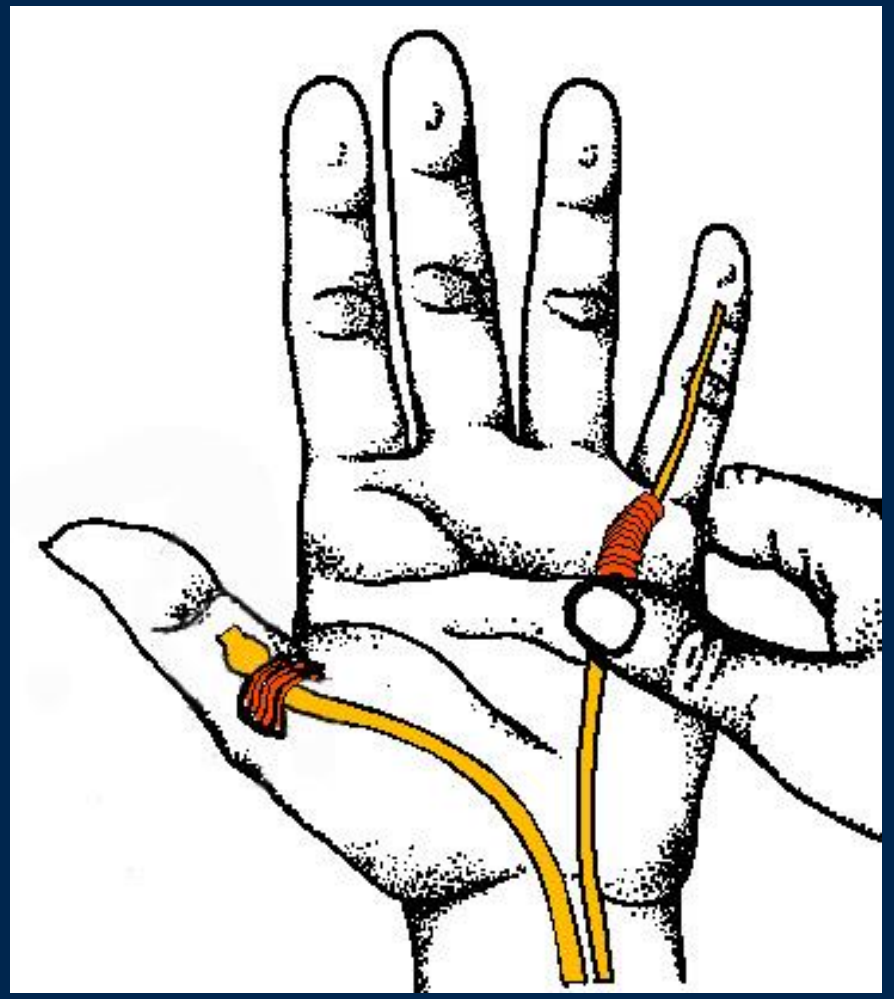

# TENDOVAGINITIS STENOSANS
## PATHOGENESE

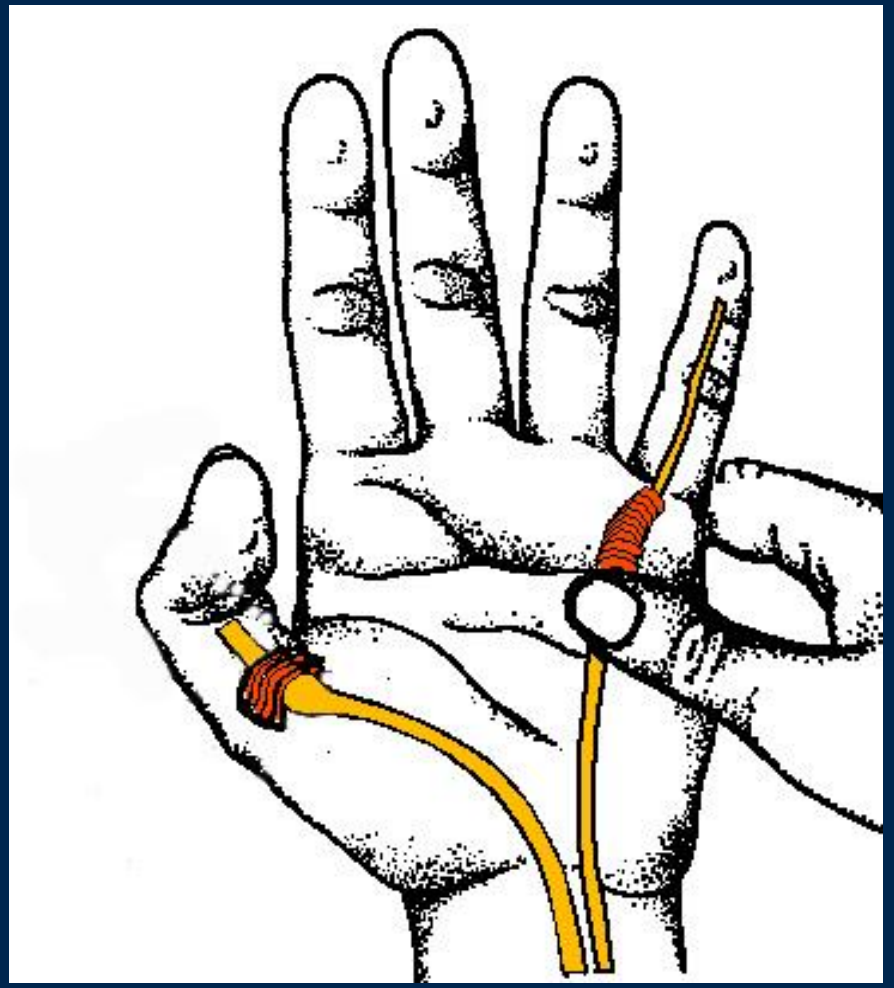

# TENDOVAGINITIS STENOSANS
## SONOGRAPHIE





# TENDOVAGINITIS STENOSANS
## SONOGRAPHIE

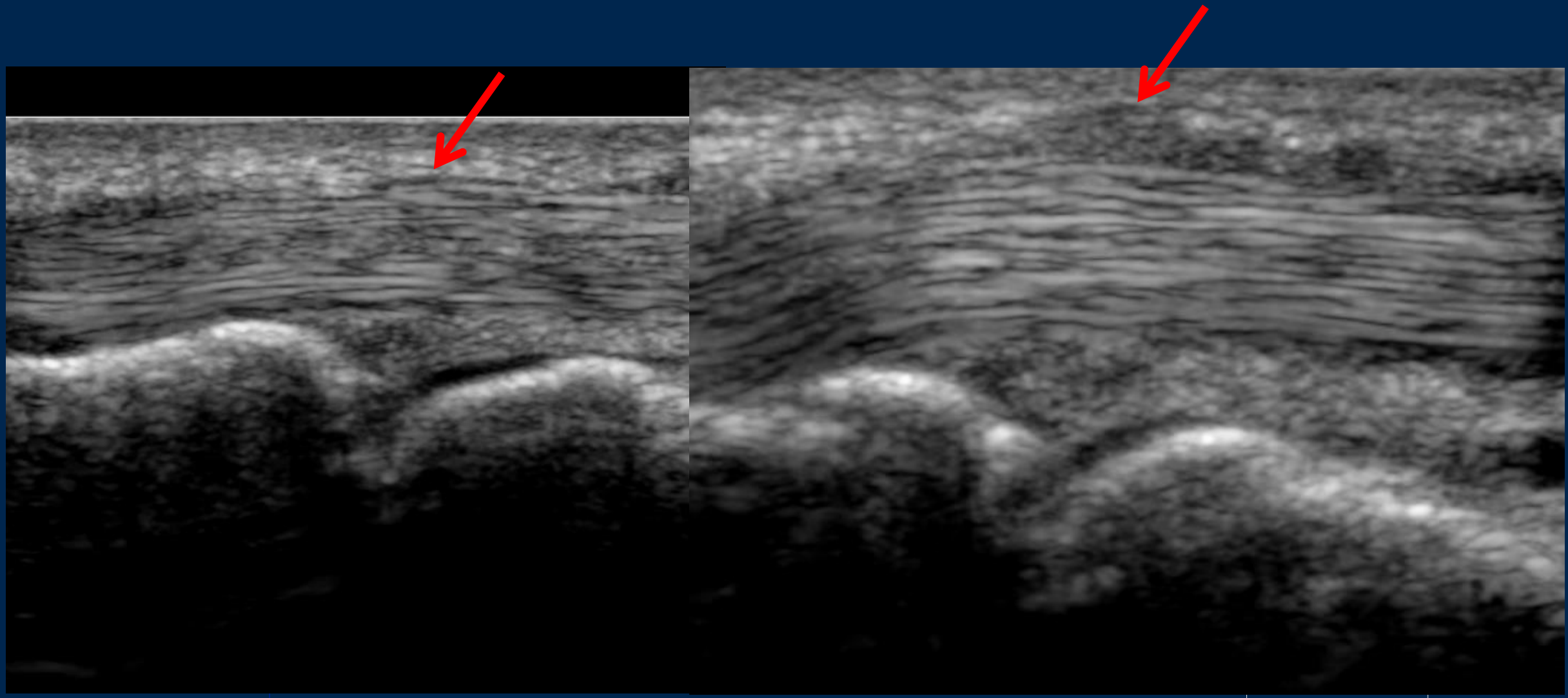

# TENDOVAGINITIS STENOSANS
## INFILTRATION MIT STEROID

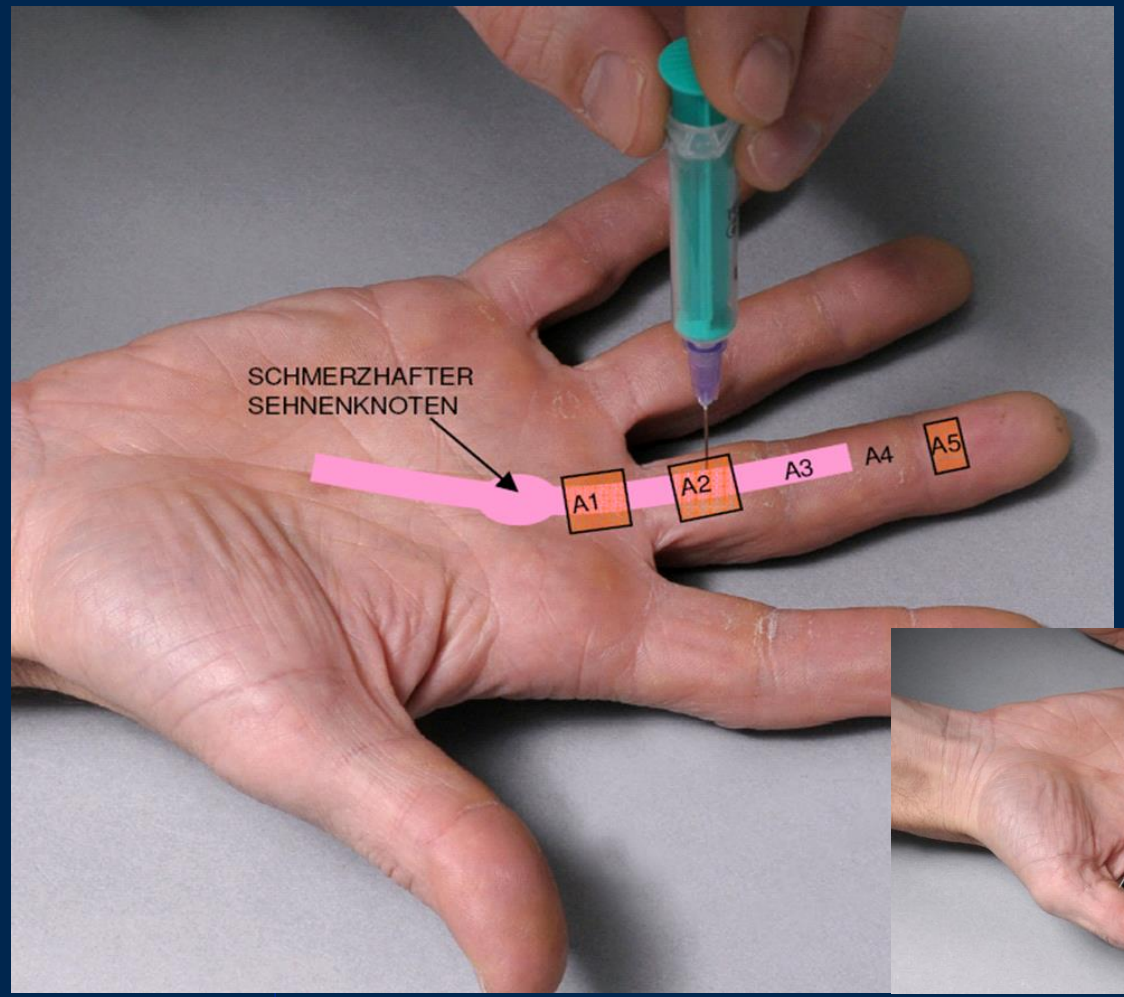


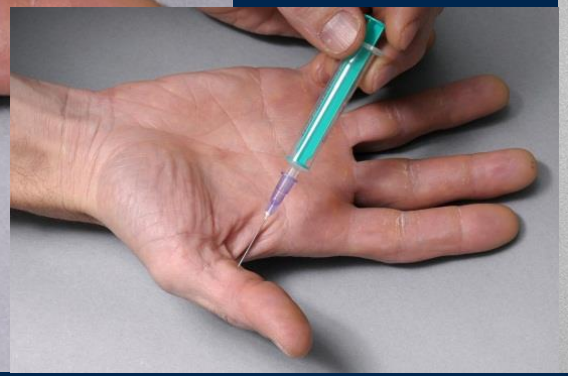

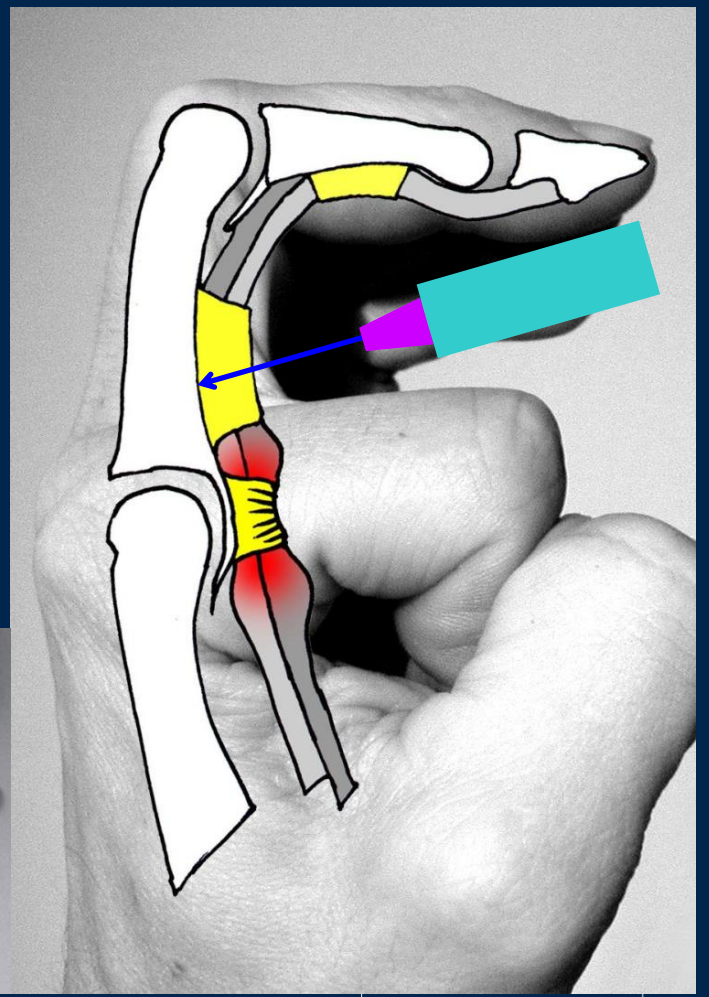

Taras1998; JHS Am:24:717-22

# TENDOVAGINITIS STENOSANS
## OPERATION

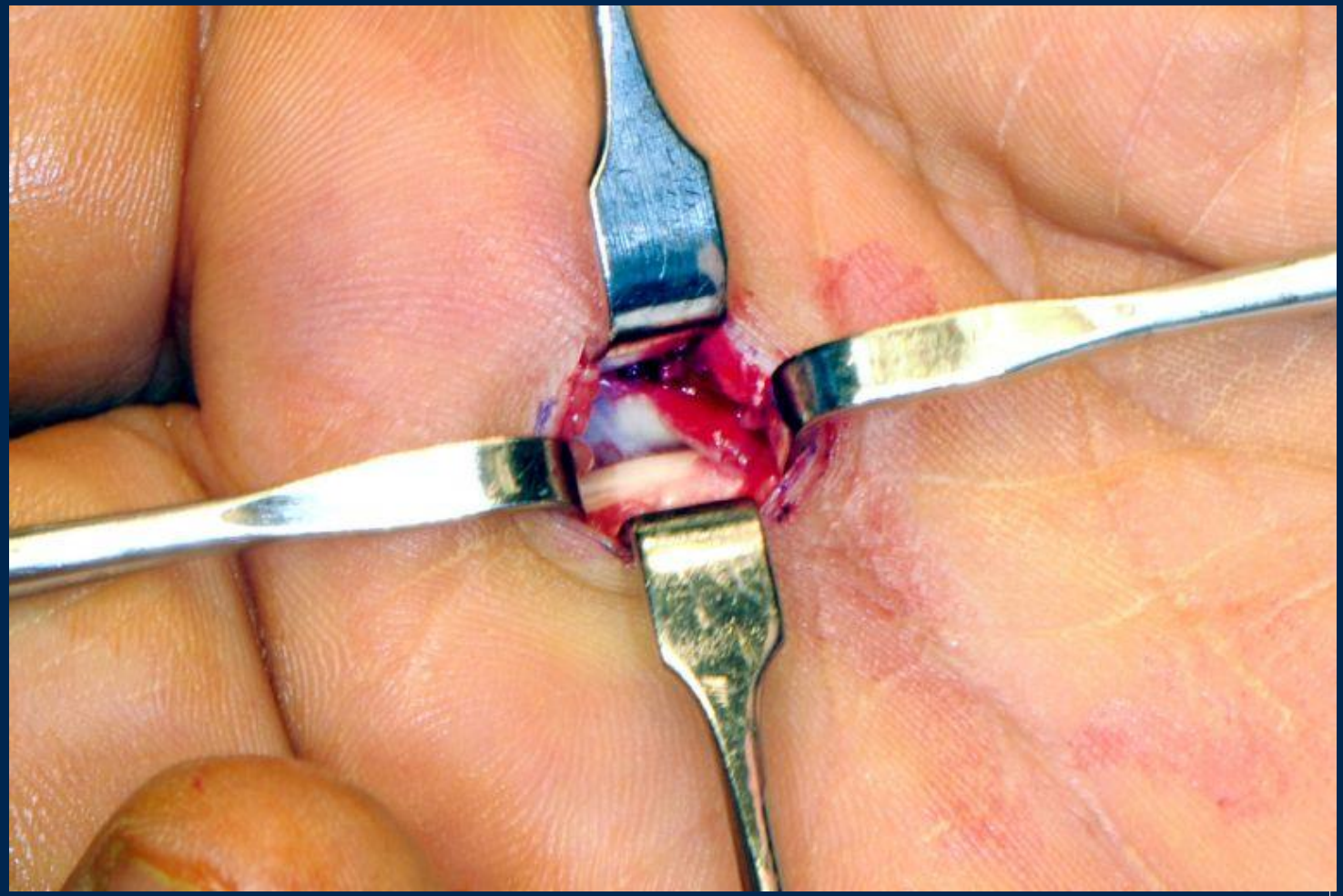

# MORBUS DUPUYTREN

- Langsam fortschreitende Bindegewebserkrankung der Palmarfaszie der Hand
- Ursache unklar, genetische Prädisposition
- Männer 5x häufiger betroffen
- Altersgipfel in 4.-5. Lebensdekade
- Zunehmende Flexionskontraktur der Fingergelenke

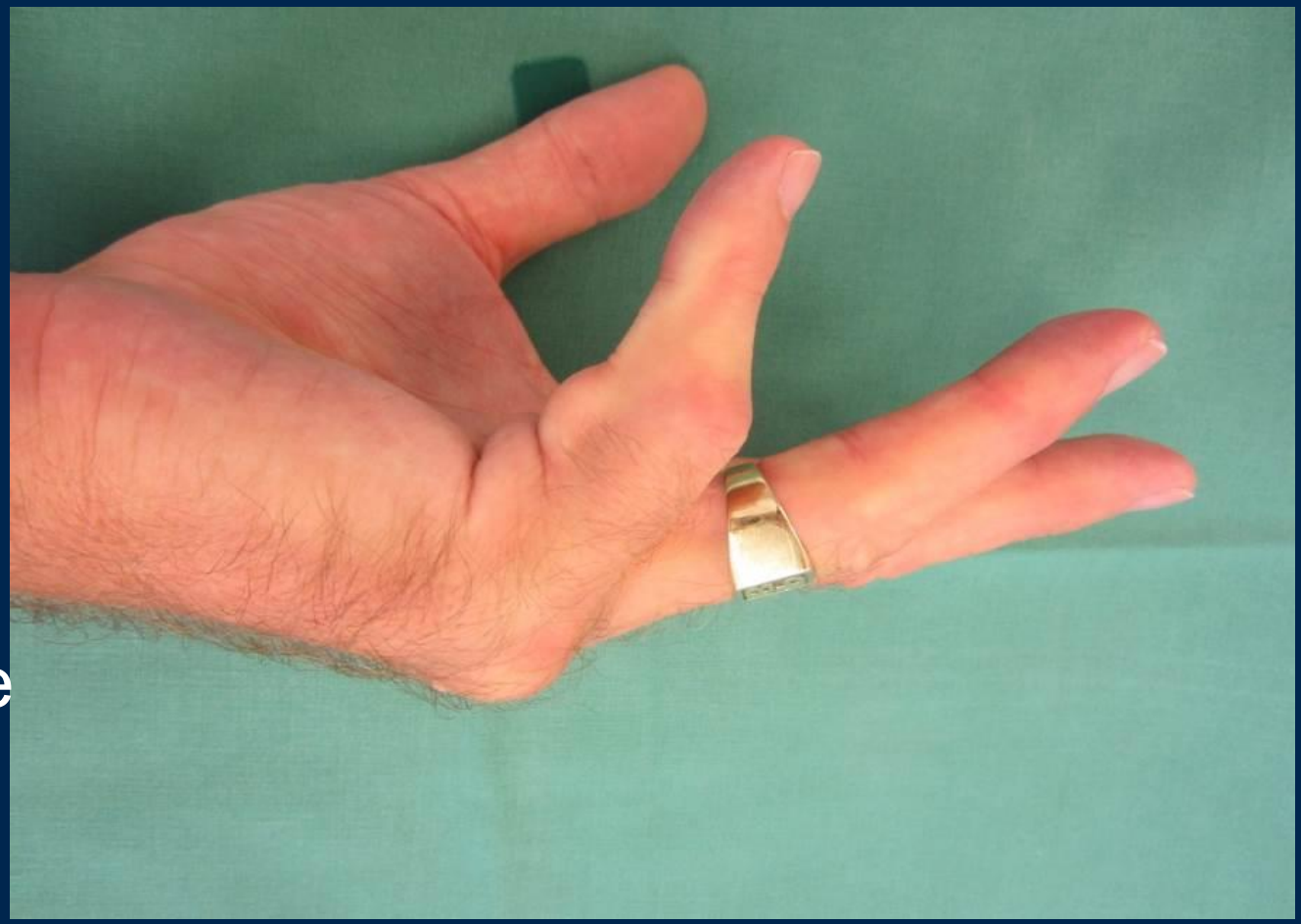

# MORBUS DUPUYTREN

- Clostridium histolyticum
- Lokale Lyse aller Kollagene mit Ausnahme von Kollagen Typ IV
- Auflösung des infiltrierten Stranggewebes



# MORBUS DUPUYTREN
## FASZIEKTOMIE



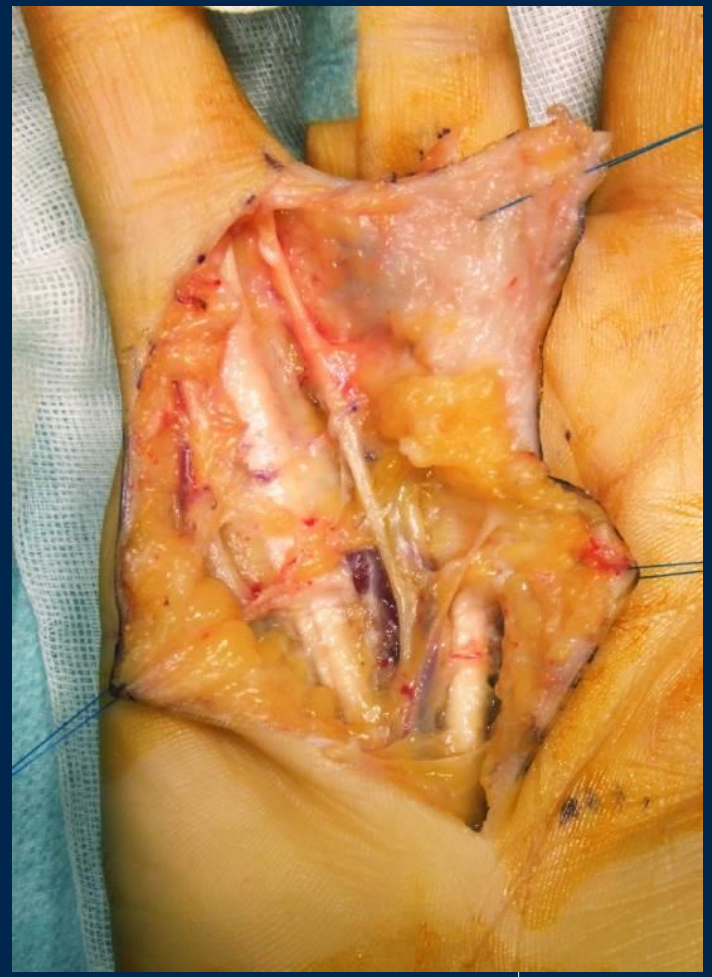

# DISTALE RADIUSFRAKTUR

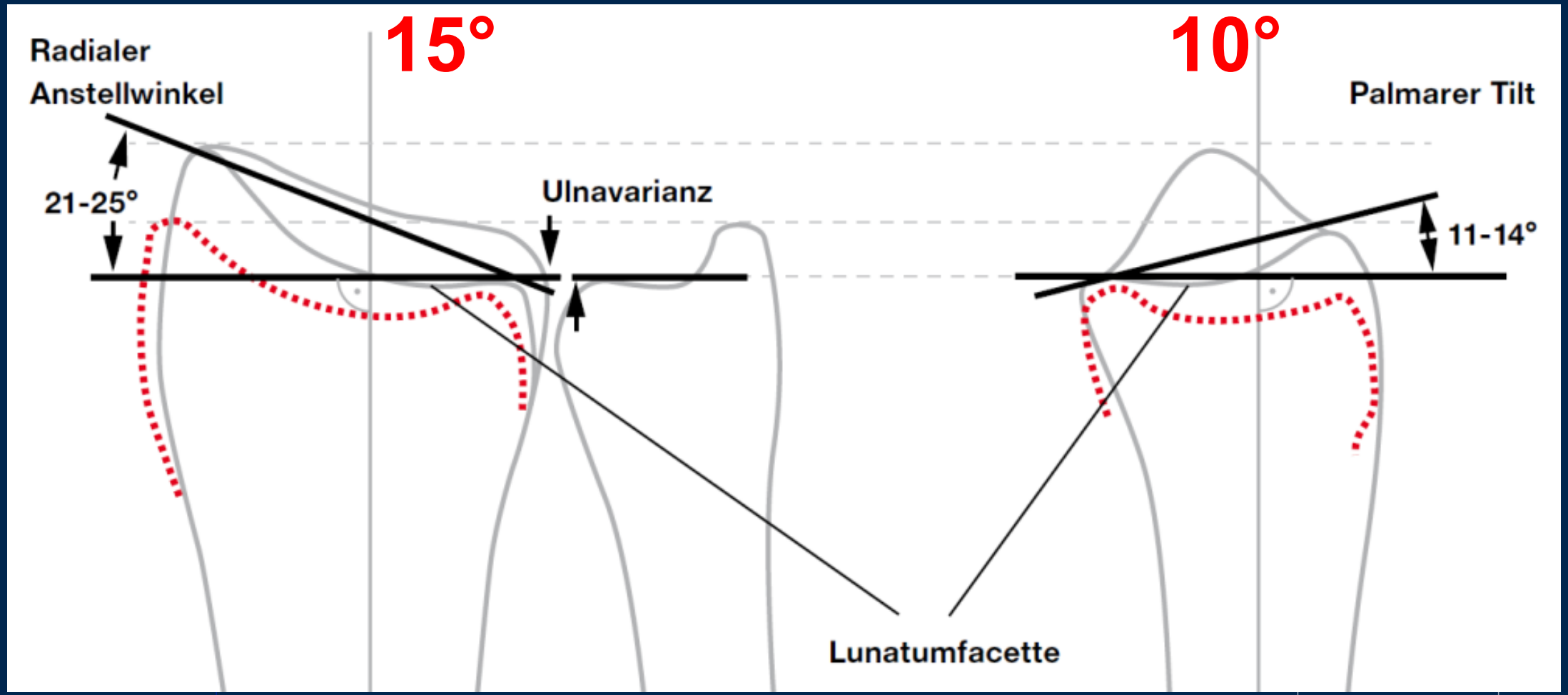

# DISTALE RADIUS FRAKTUR
## KONSERVATIV




28 J.

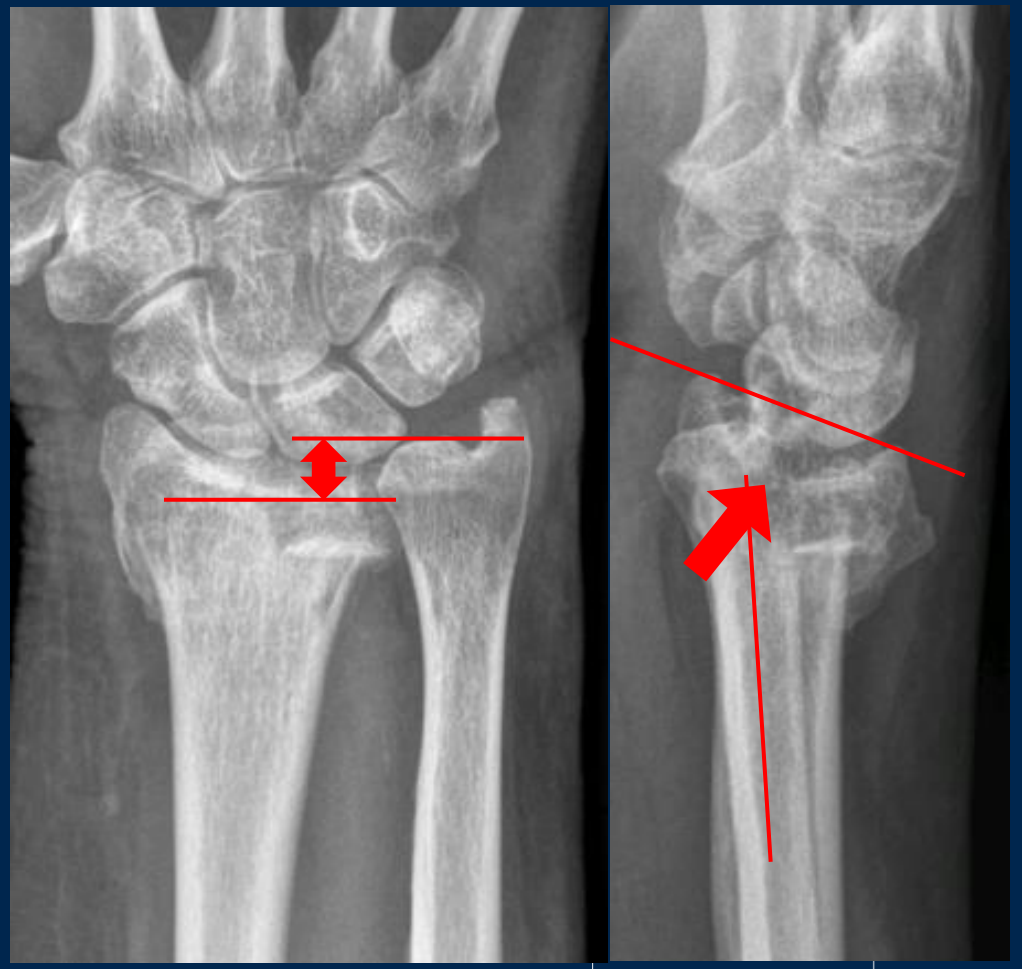

74 J.

# DISTALE RADIUS FRAKTUR

## KONSERVATIV «ALLE» > 65 ->75









Arora et al. J Bone Joint Surg Am 2011; 7;93(23):2146-53

# MALUNION

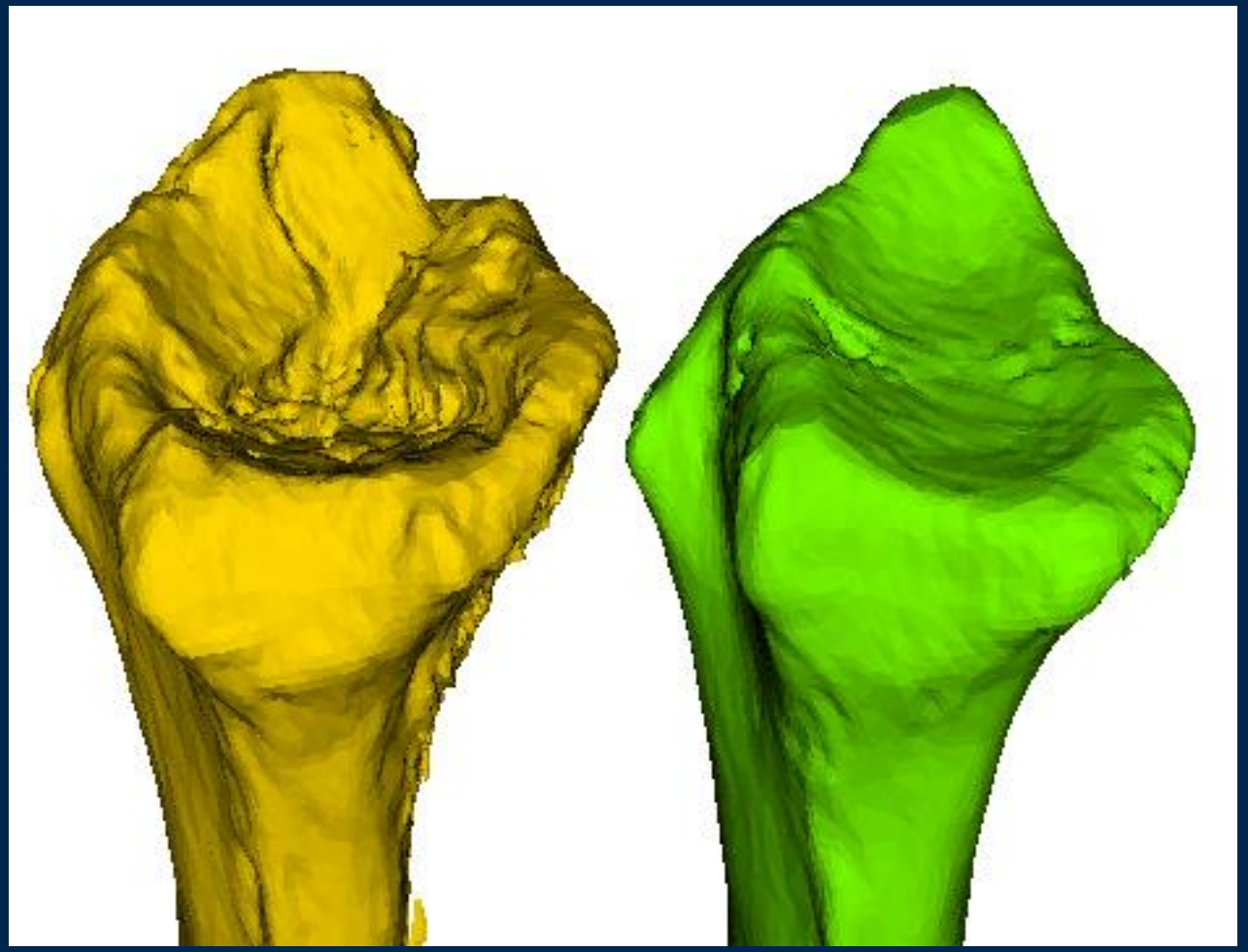

# MALUNION
## KOMPLEXE KORREKTUROSTEOTOMIE



# DISTALES RADIOULNARGELENK / TFCC
## (Triangulärer fibrokartilaginärer Komplex: Arthro MRI

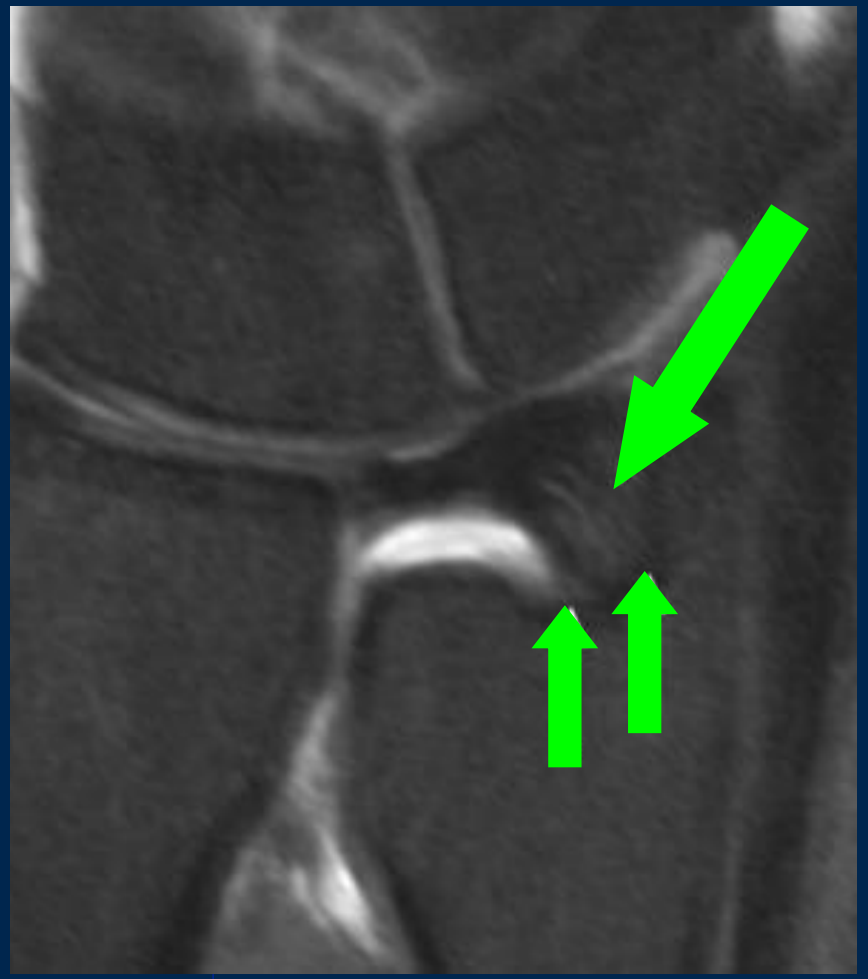

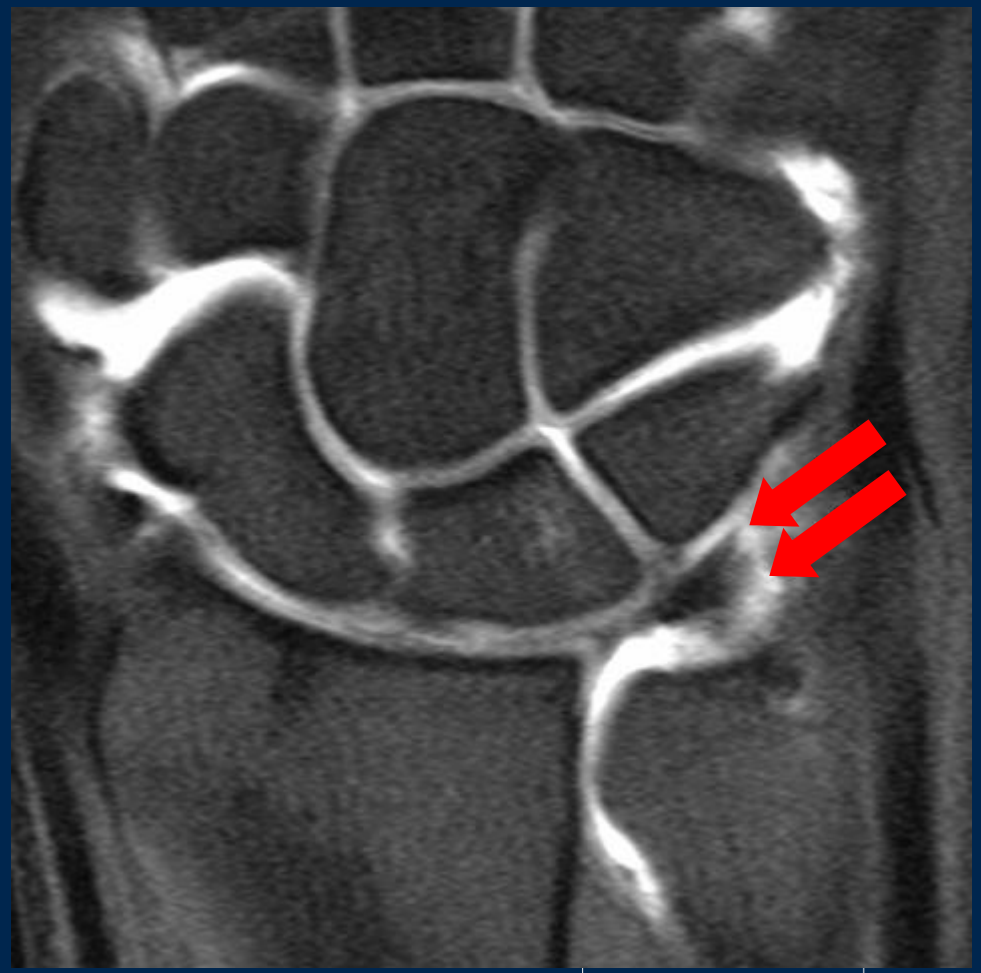

# TFCC - LÄSION

## KLINIK



# TFCC - LÄSION
## KONSERVATIVE THERAPIE

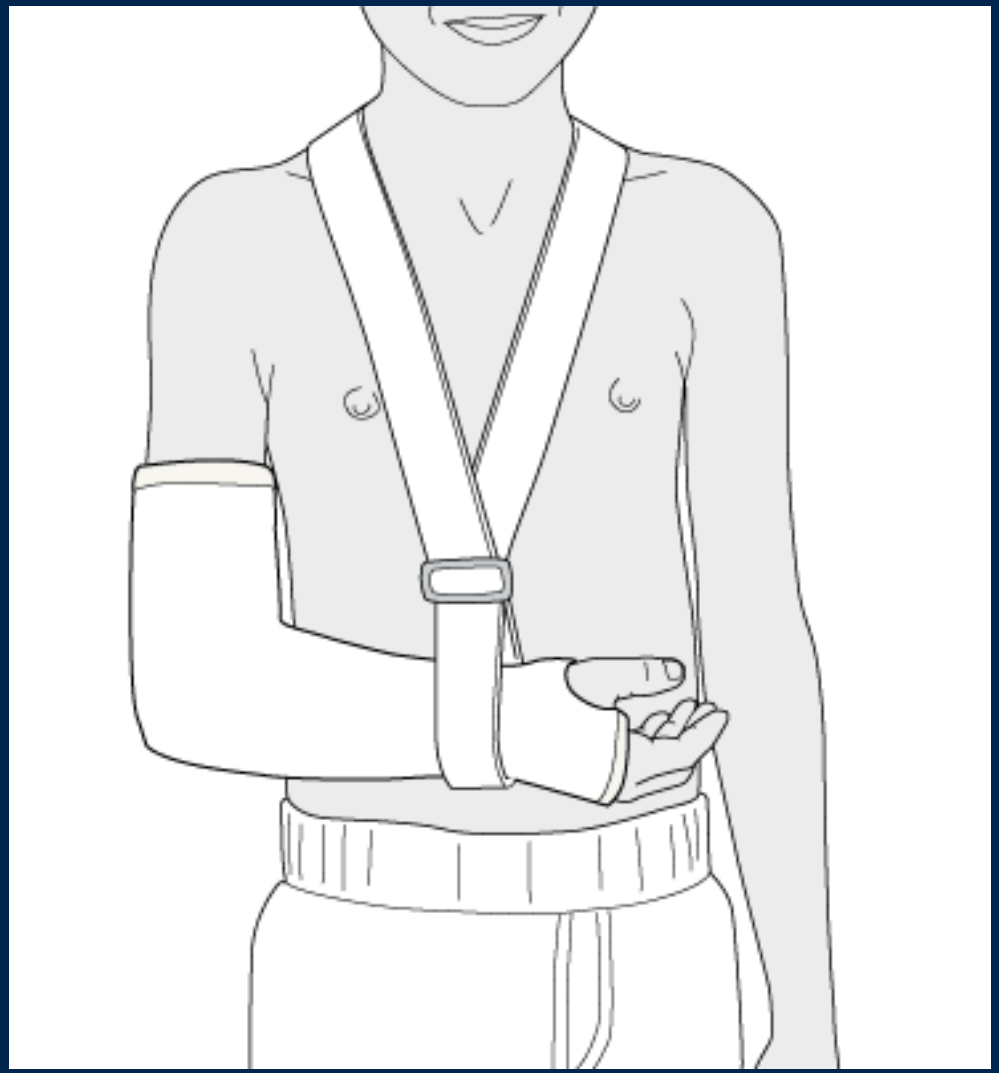

# TFCC - LÄSION
## OPERATION

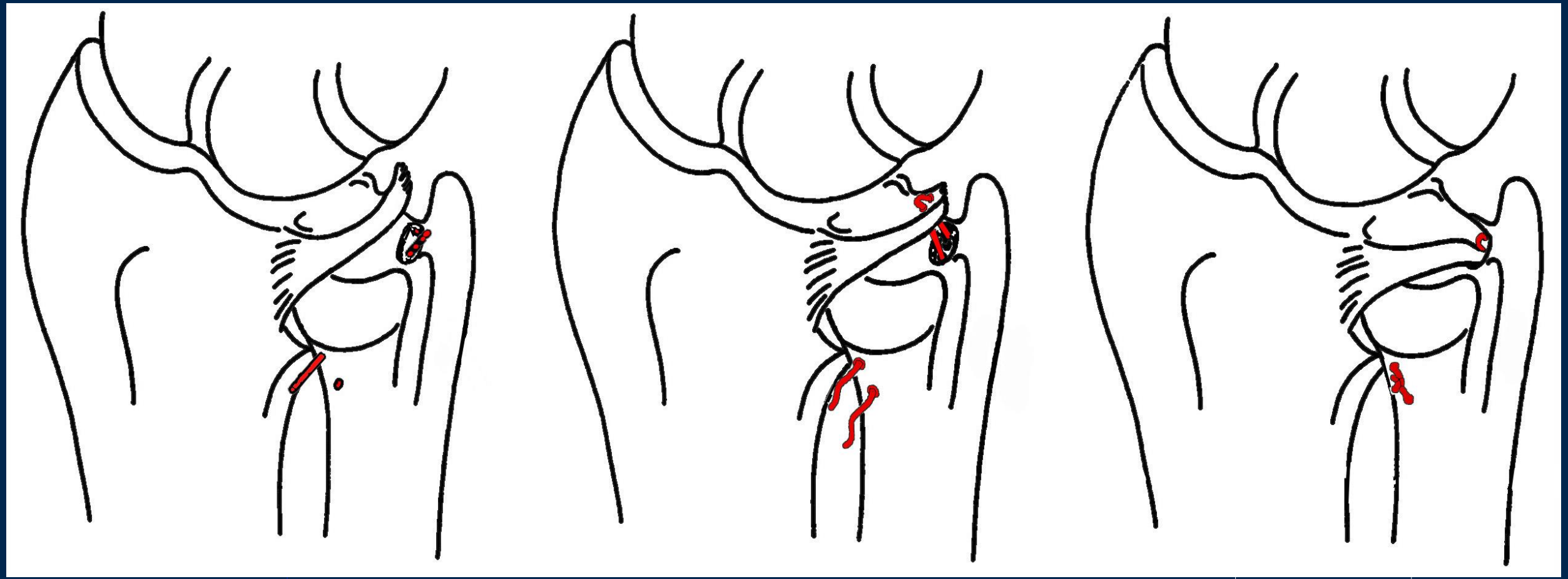

# TFCC - LÄSION
## OPERATION

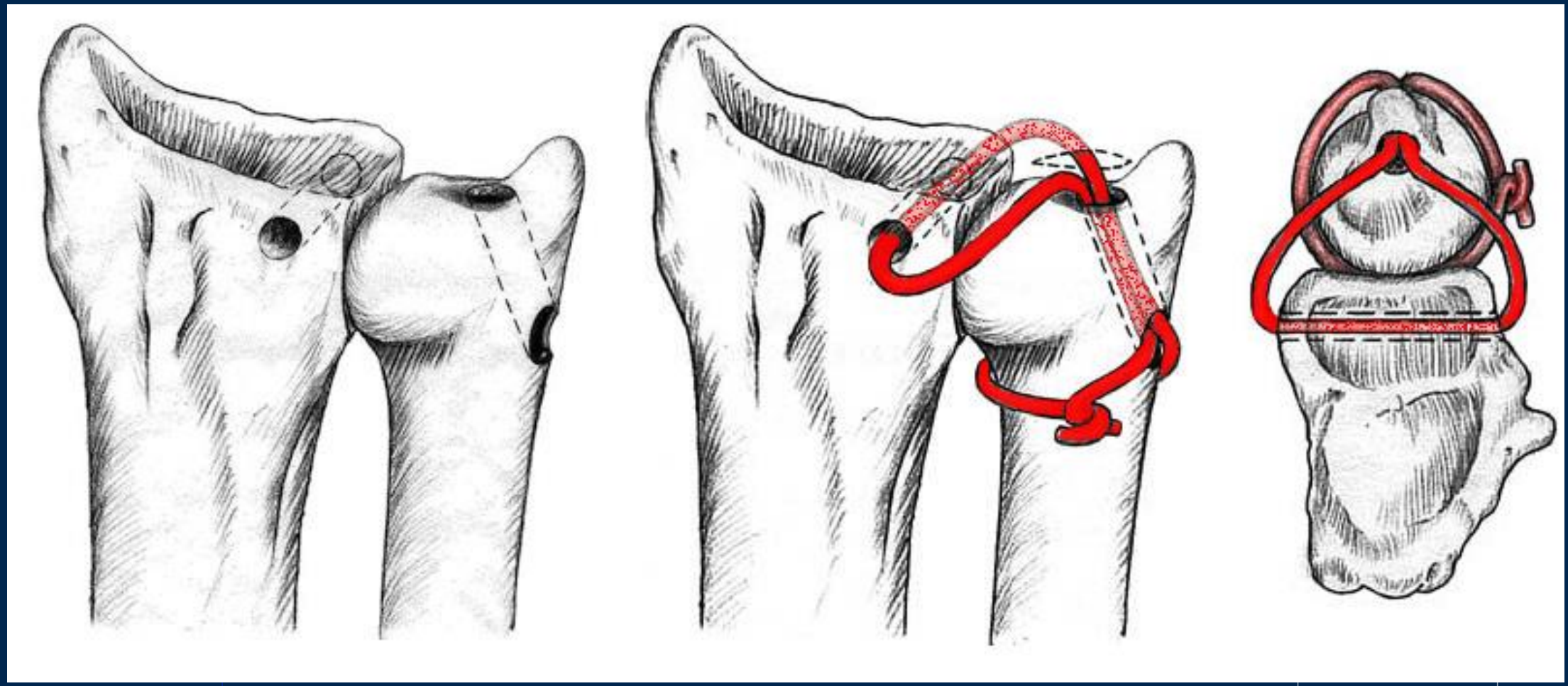

Adams BD & Berger RA 2002; JHS 27A: 243-251

# ZENTRALE TFCC-LÄSION
## ULNAKARPALES IMPAKTIONSYNDROM

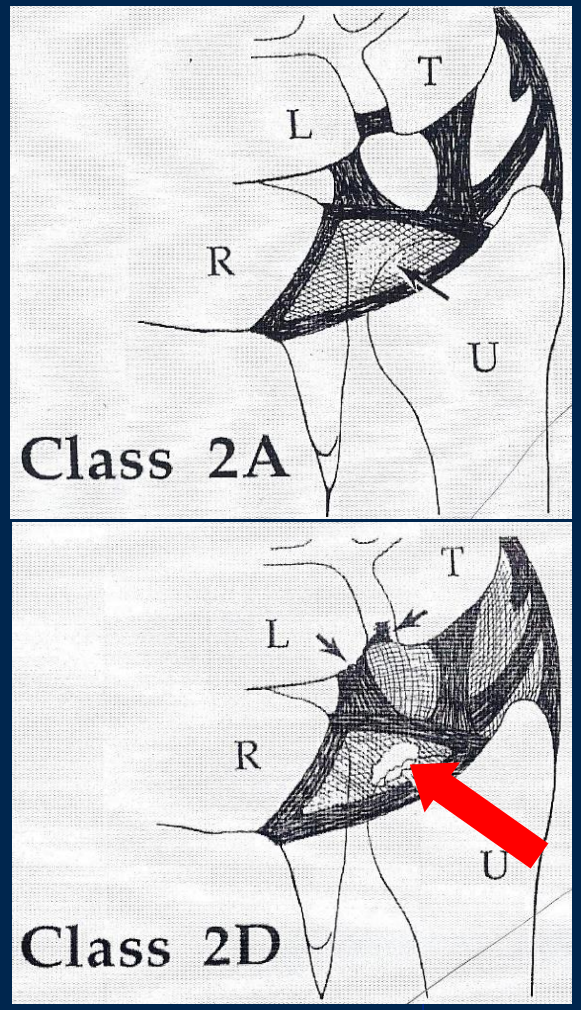






# ULNOKARPALES IMPAKTATIONSSYNDROM
## PROVOKATIONSTEST



# ULNOKARPALES IMPAKTATIONSSYNDROM
## ULTRASCHALLGESTEUERTE STEROIDINFILTRATION

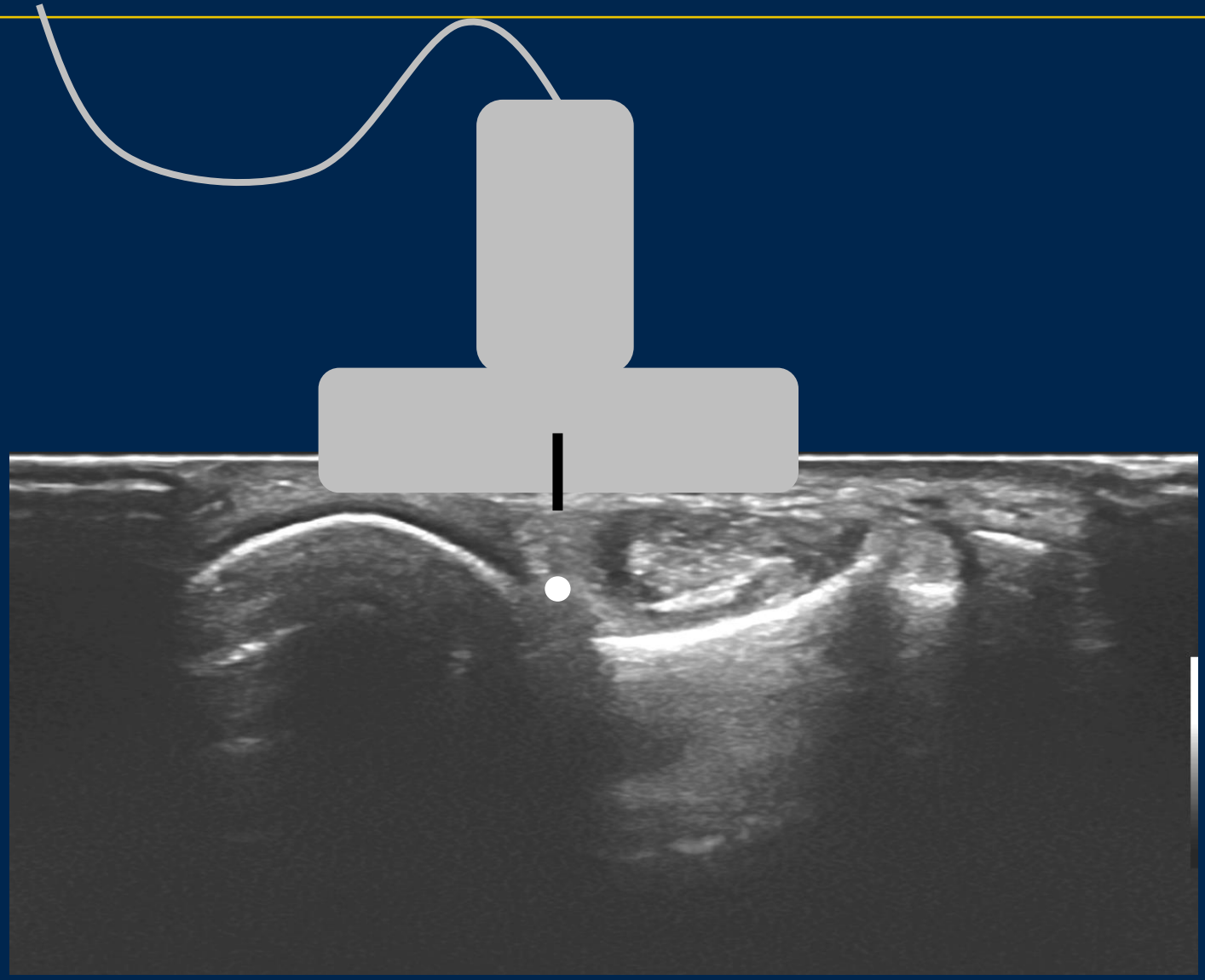

# ULNOKARPALES IMPAKTATIONSSYNDROM
## ULNAVERKÜRZUNGSOSTEOTOMIE





# HANDGELENK TRAUMA / DISTORSION

- > 2 -3 Wochen Schmerz ohne Besserung = Abklärung
- Bandverletzung SL mittels Arthro-MRI

# SKAPHOLUNÄRE BANDRUPTUR
## ARTHRO-MRI/RÖNTGEN

RL >15°

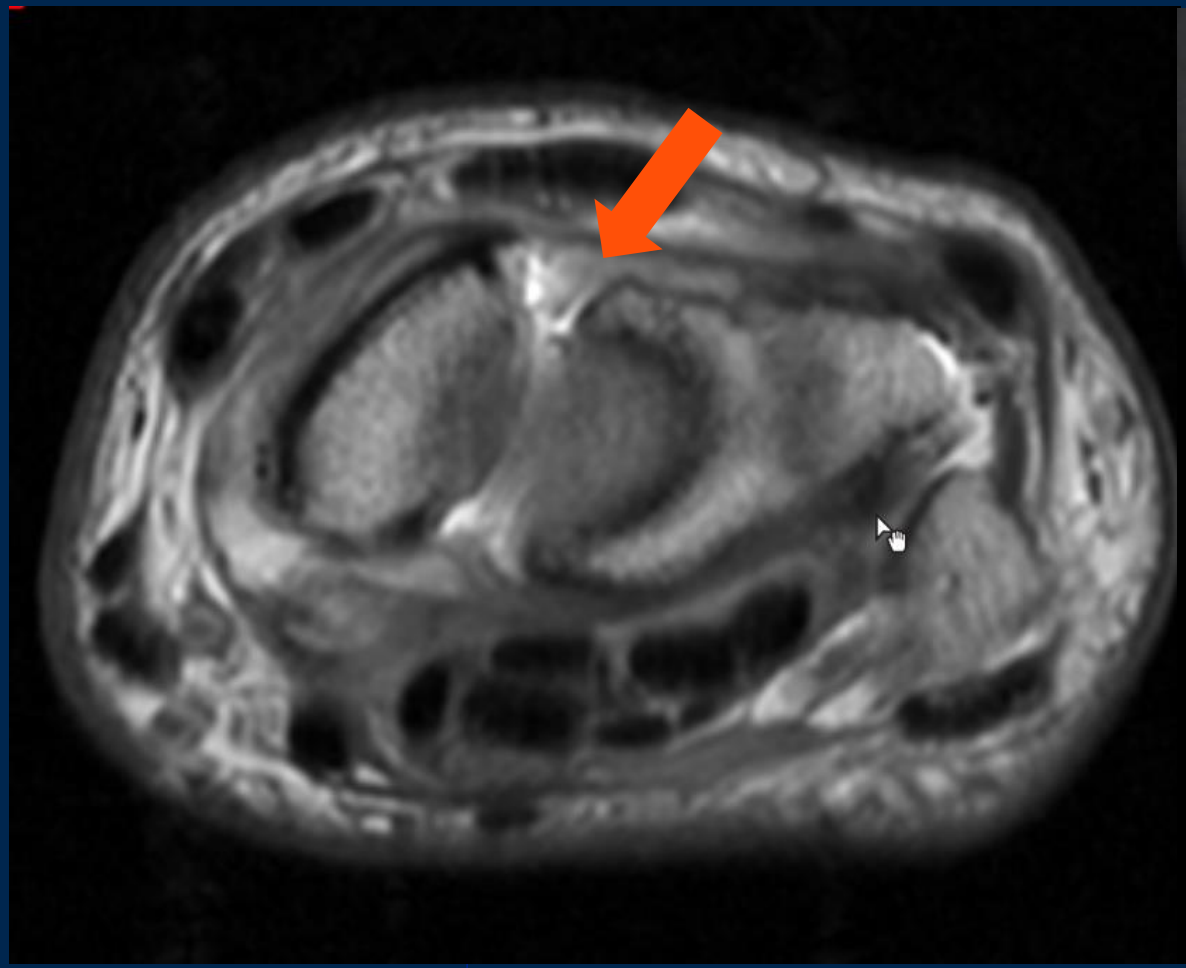



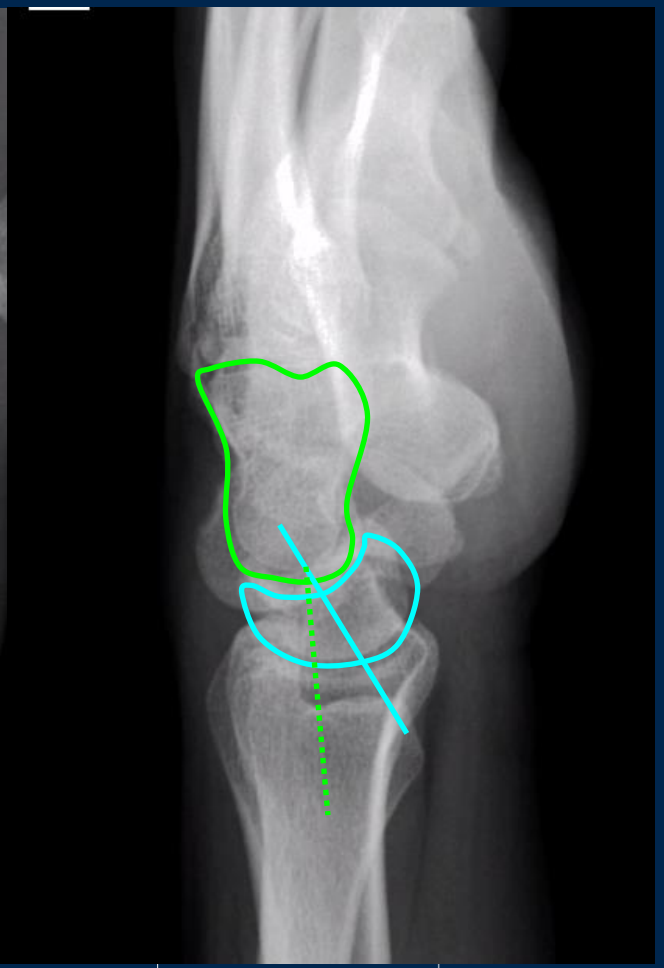

# SKAPHOLUNÄRE BANDRUPTUR
## PATHOMECHANISMUS





# SKAPHOLUNÄRE BANDRUPTUR
## WATSONTEST



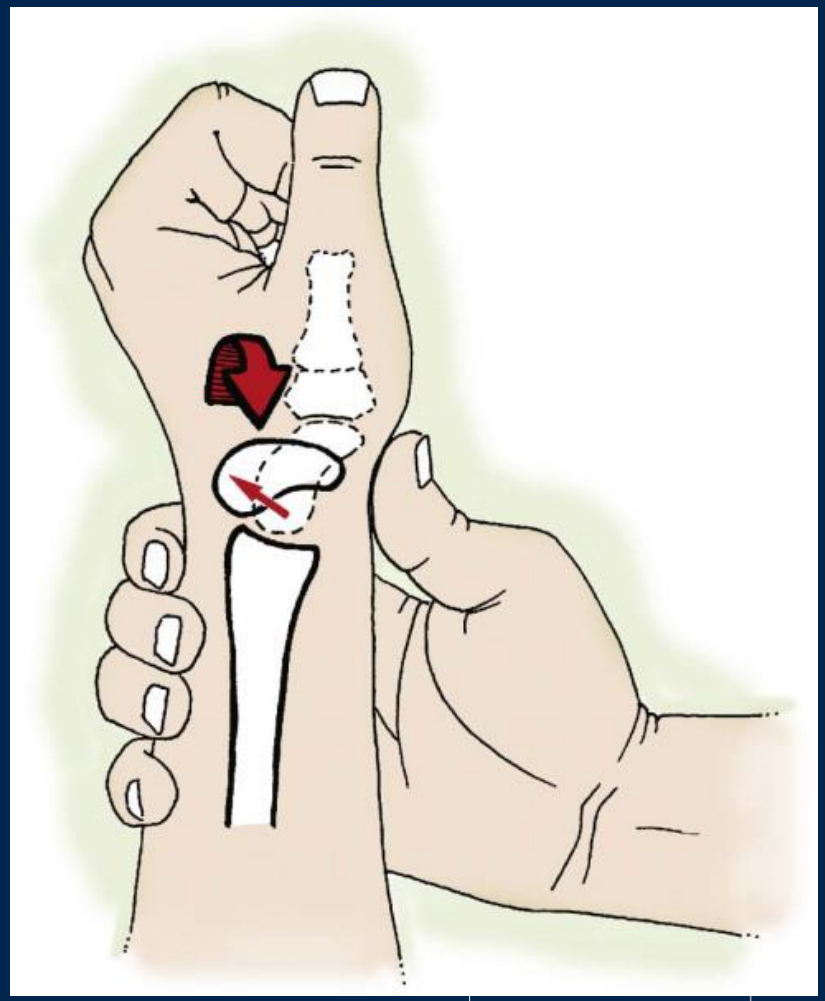

# SKAPHOLUNÄRE BANDRUPTUR
## INTRAOPERATIV

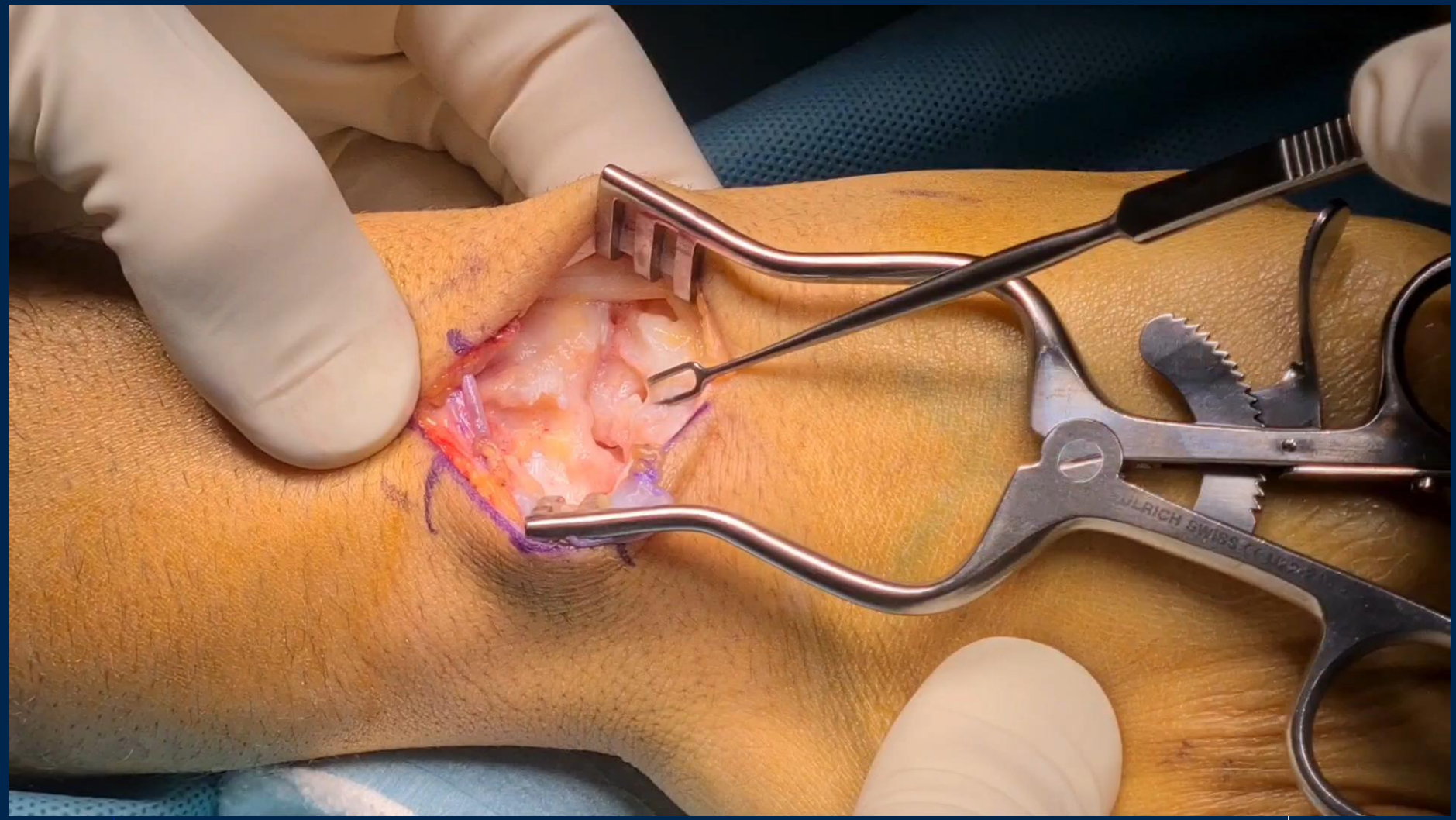

# SKAPHOLUNÄRE BANDRUPTUR
## OPERATIONSTECHNIK

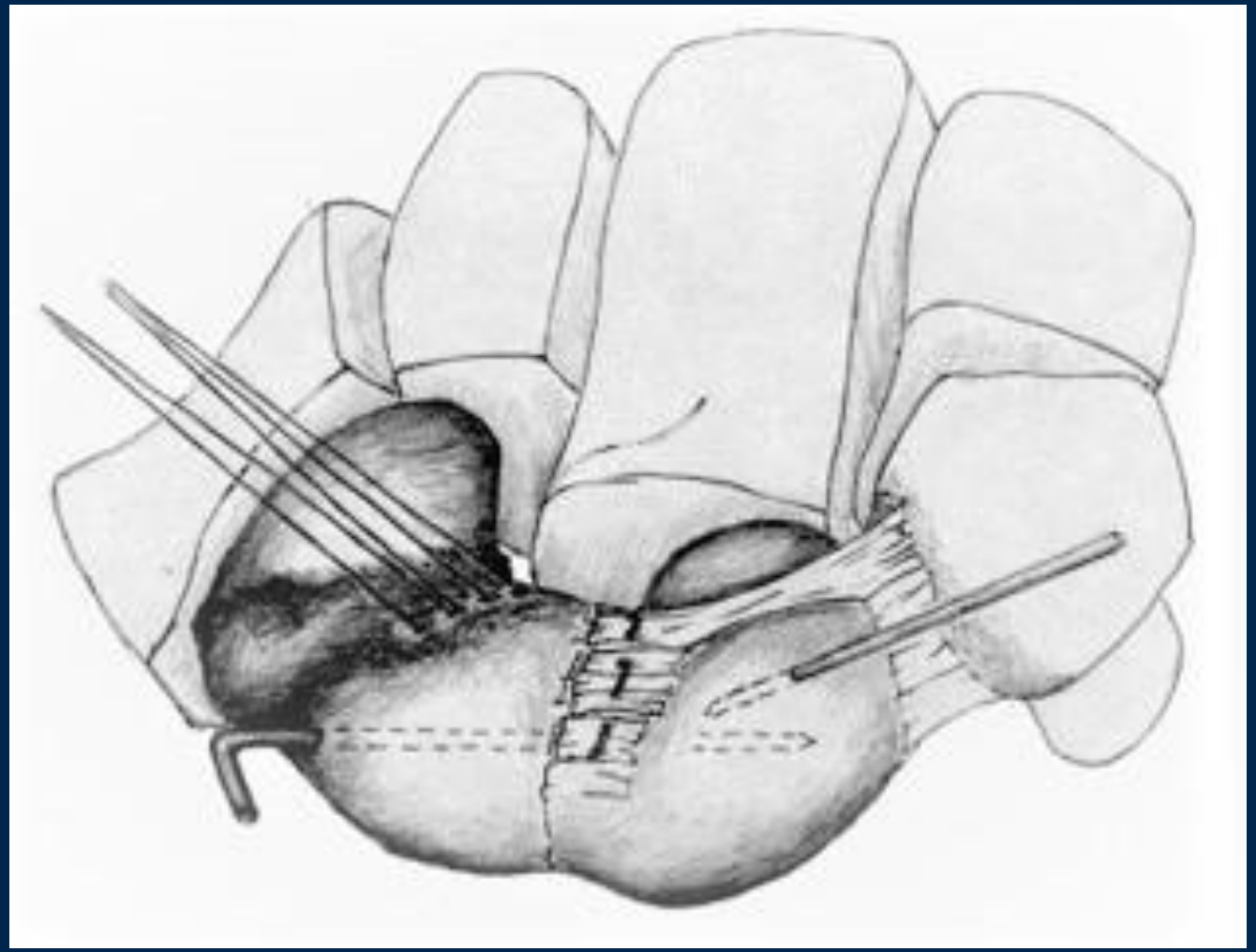

# SKAPHOLUNÄRE BANDRUPTUR
## OPERATIONSTECHNIK

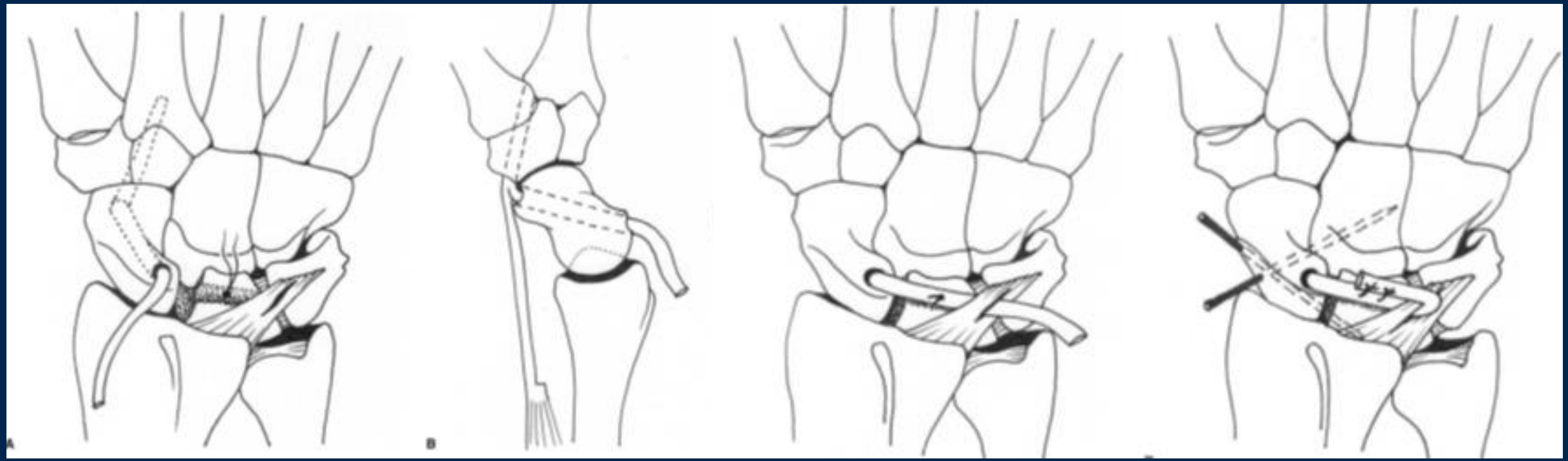

# SKAPHOLUNÄRE BANDRUPTUR
## OPERATIONSTECHNIK



# SLAC
## THERAPIEOPTIONEN






# HERZLICHEN DANK

Lisa.reissner@balgrist.ch